Embolisation of cerebral AVMs

R. Chapot
AKK, Essen
chapot@online.fr

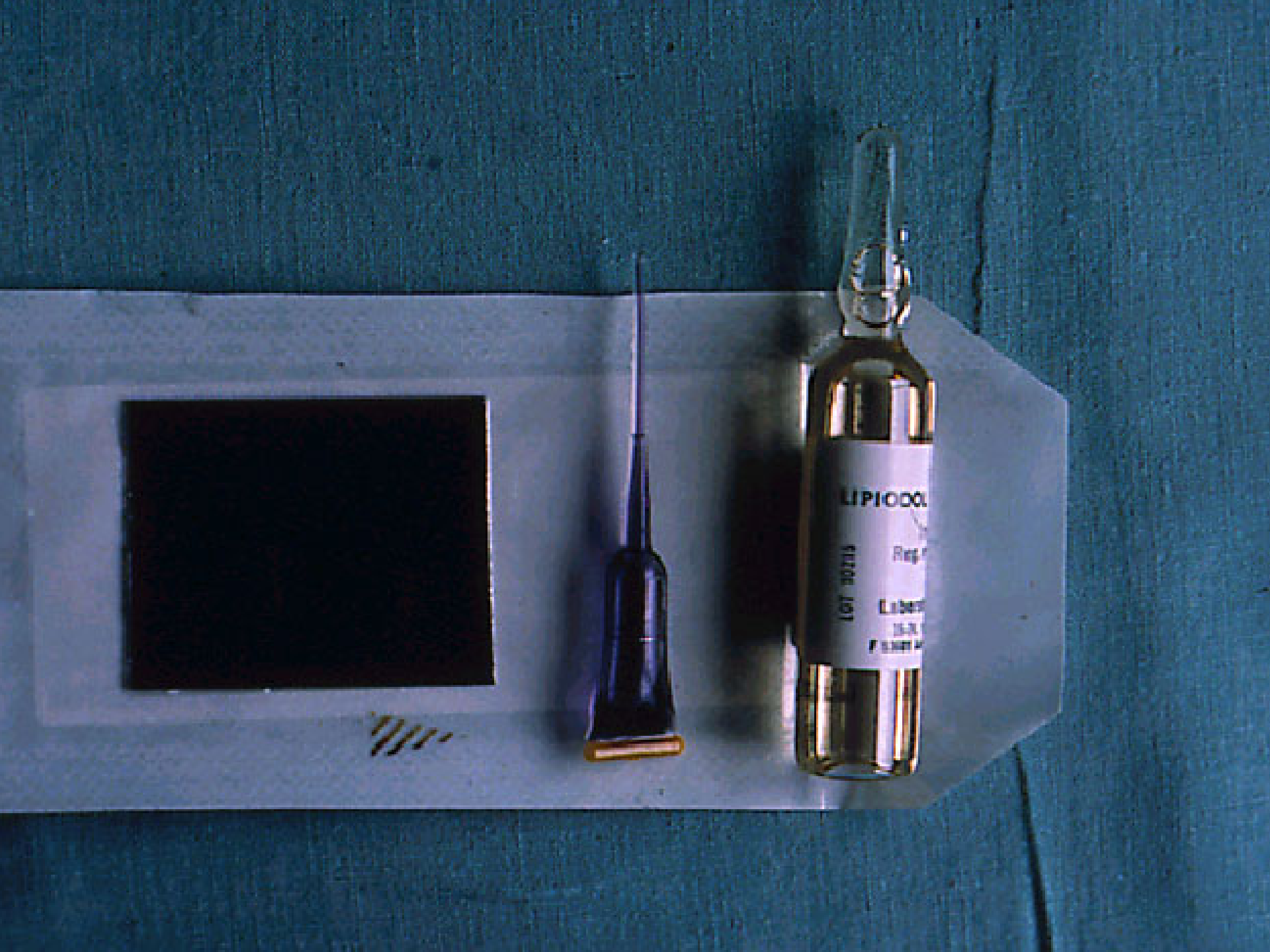
LIPIODOL

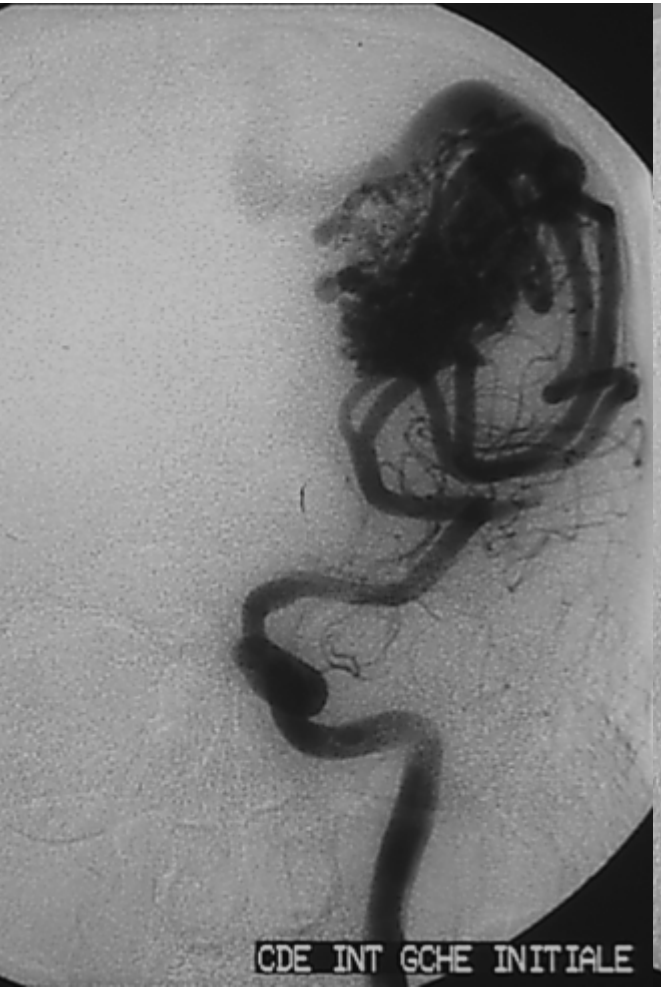
CDE INT GCHE INITIALE

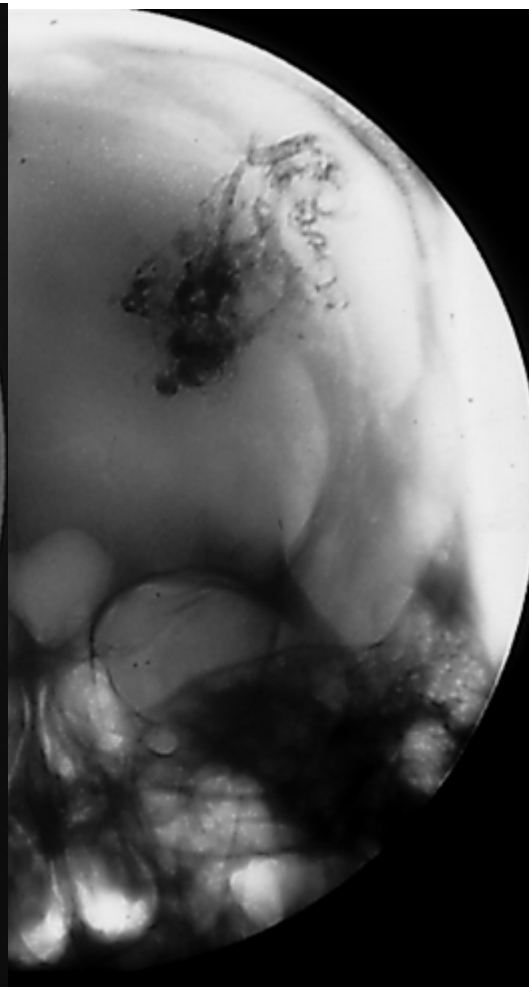

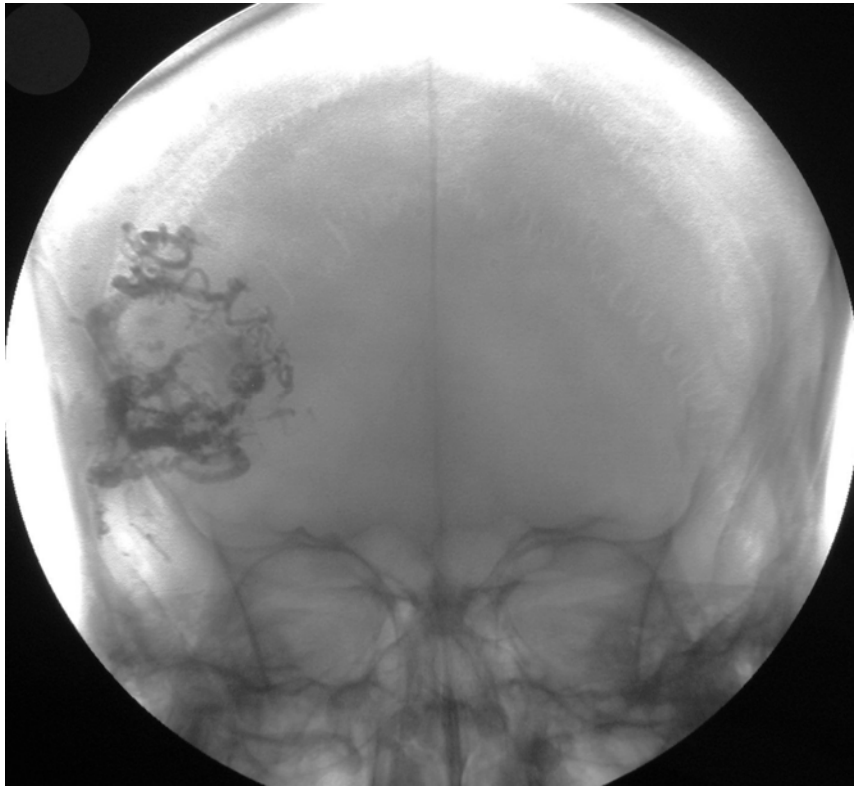

Occlusion of disconected compartments

Onyx

FOR EXPORT ONLY
Onyx® 18
REF 105-7000
LOT 5903873
Onyx
FOR EXPO
Onyx® 18
REF 105-7000
LOT 5903873
Onyx
1.5 ml

VORTEX-GENIE 2
VORTEX-GENIE 2

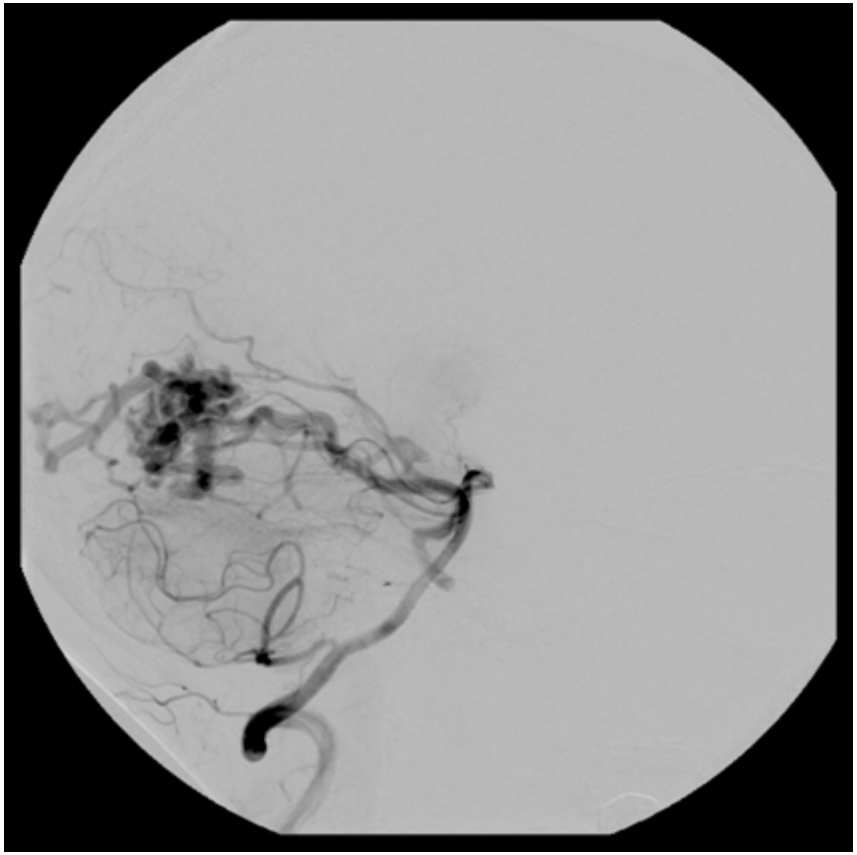

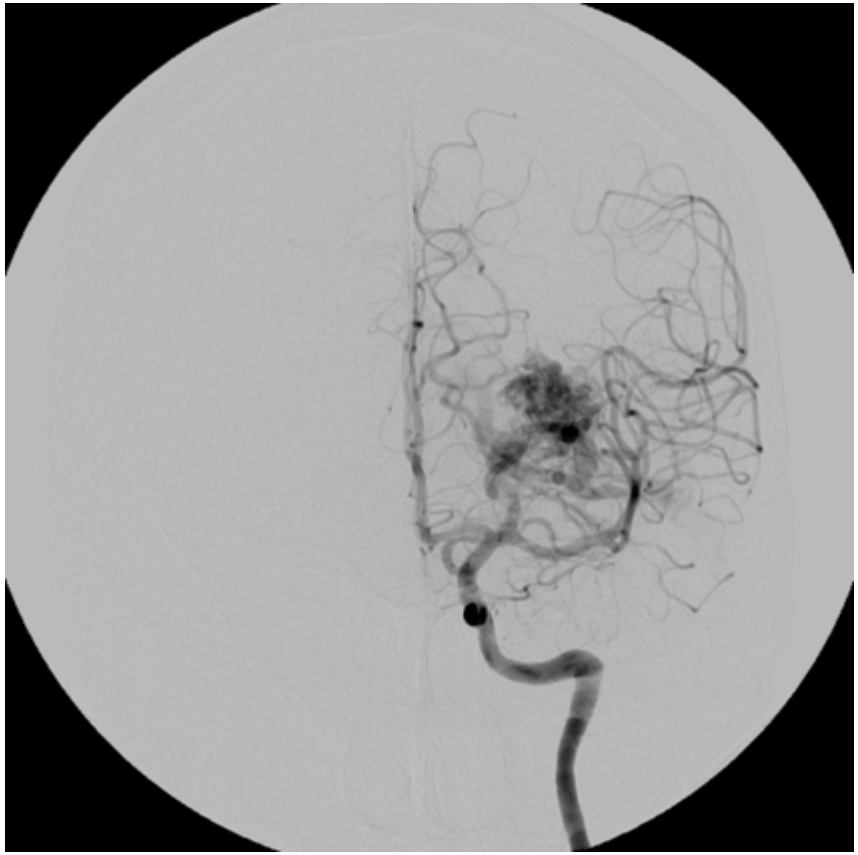

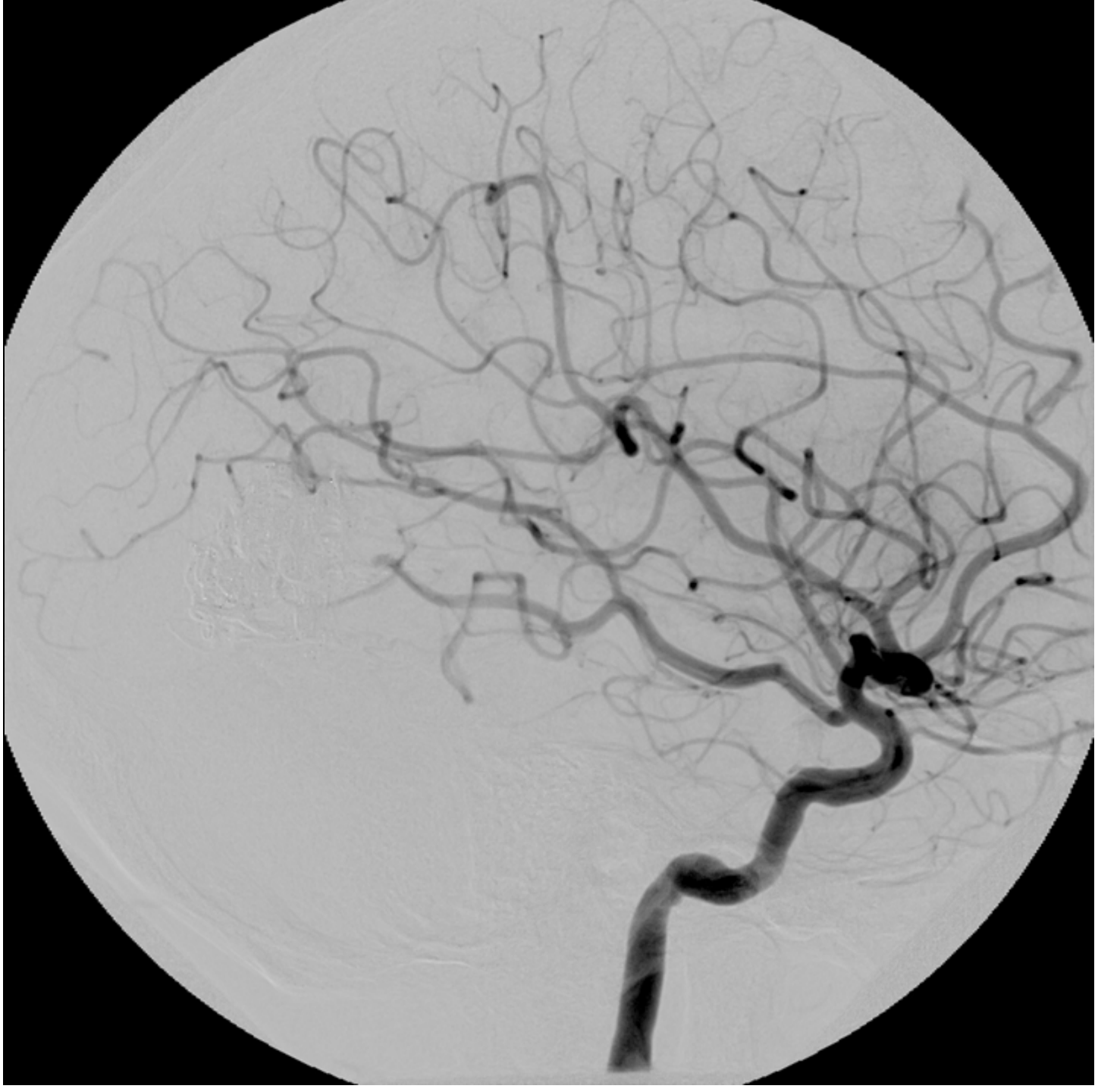

Onyx

- Polymer + Solvant (DMSO)

- DMSO :
  - Local toxicity
  - Systemic toxicity +++

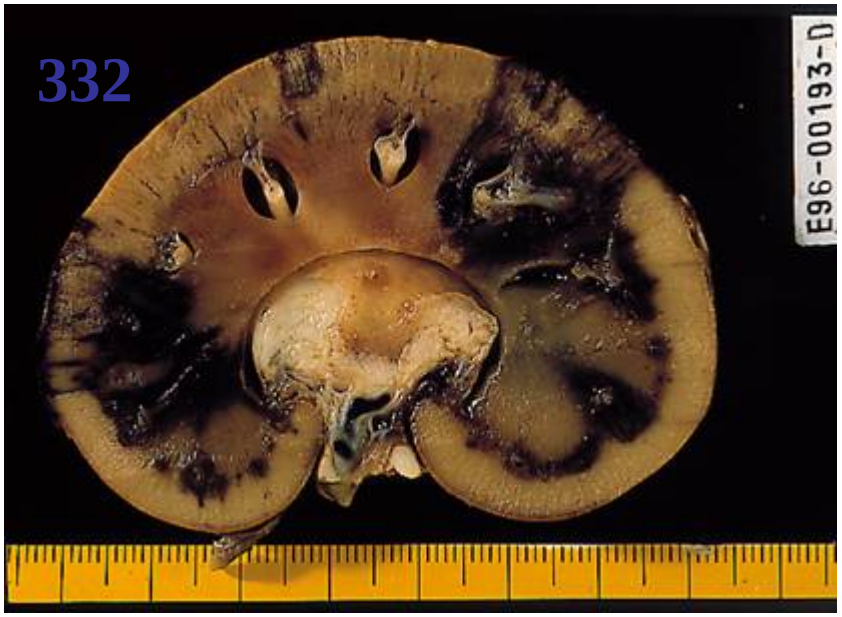

DMSO 1ml x 5 distal

Distal Reflux at Microcatheter



Reflux

- Which length of reflux?
- When to retrieve microcatheter?

04
que:
e:
MAS

Reflux

- How long ?
- When to retrieve microcatheter?
- Detachable tip

25-06-1975 F
476340
11-07-2006
PR R CHAPOT
ROT
-41
ANG
-1
SEQ.
9
25
IMAGE
Tps-image:
2.80
Tps-seq:

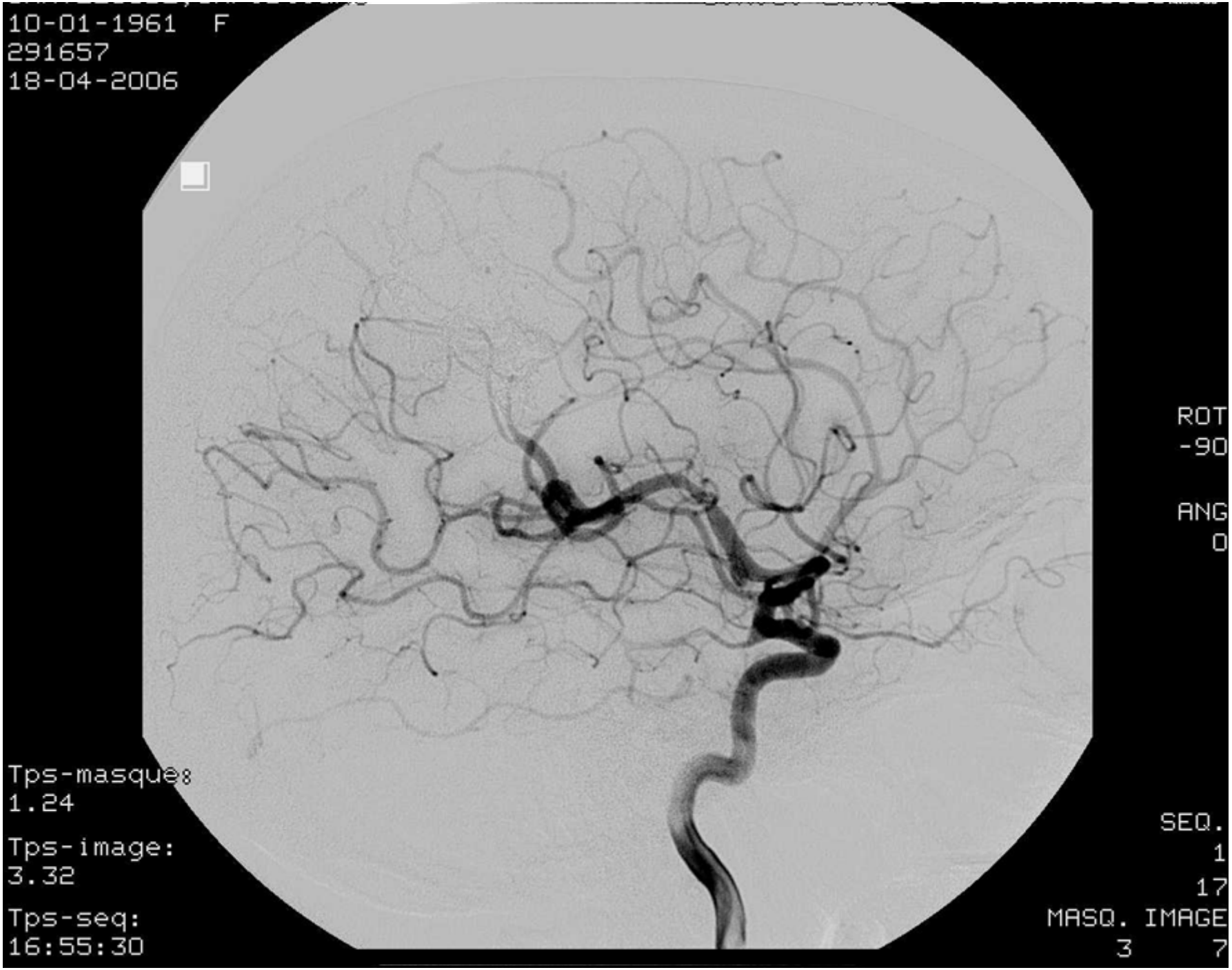
10-01-1961 F
291657
18-04-2006
ROT
-90
ANG
0
Tps-masque:
1.24
Tps-image:
3.32
Tps-seq:
16:55:30
SEQ.
1
17
MASQ. IMAGE
3 7

Reflux

- How long ?
- When to retrieve microcatheter?
- Detachable tip
- Trapping due to diffusion through anastomoses

Distal Reflux at Microcatheter

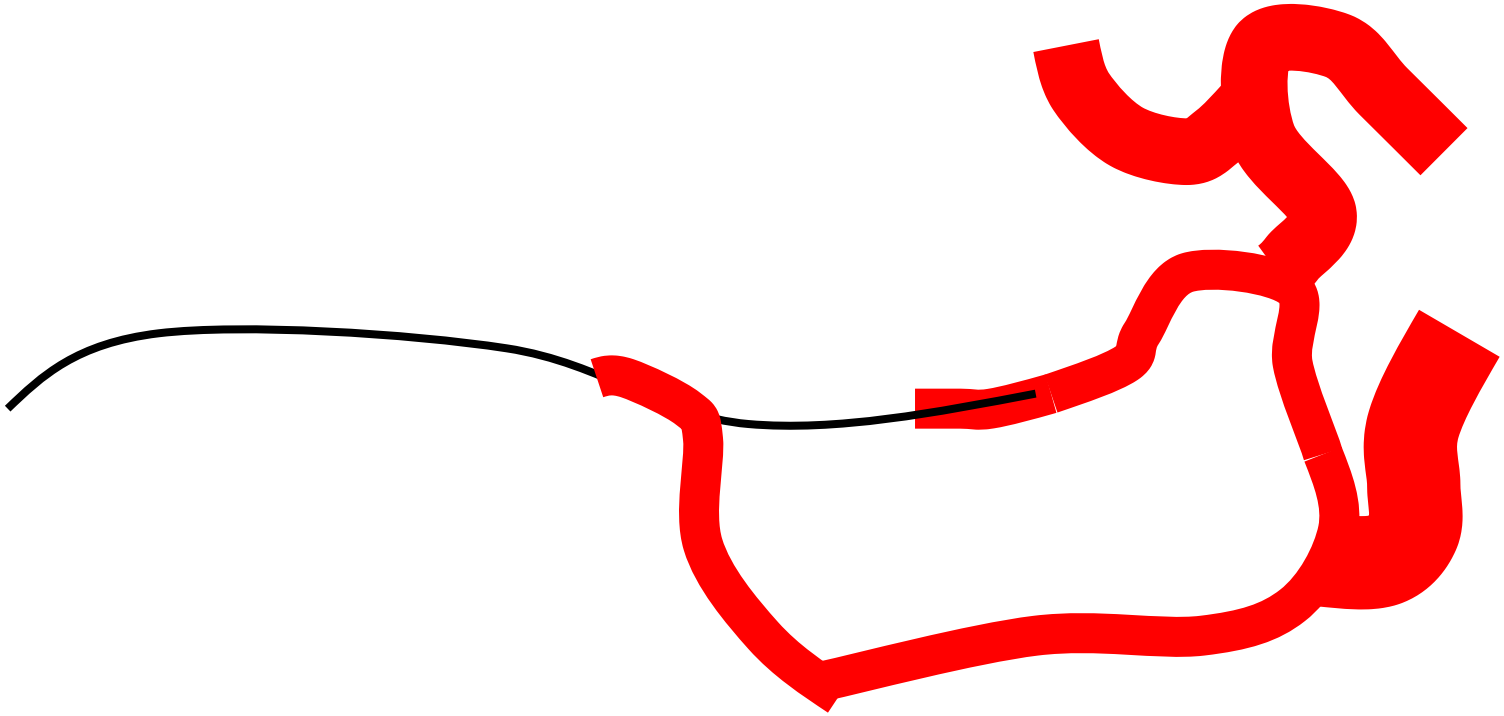

Angioarchitecture

- Compact
- Macrofistula
  - Balloon & Histoacryl
  - Coils & Onyx
- En passant feeder
- Diffuse
- Aneurysm

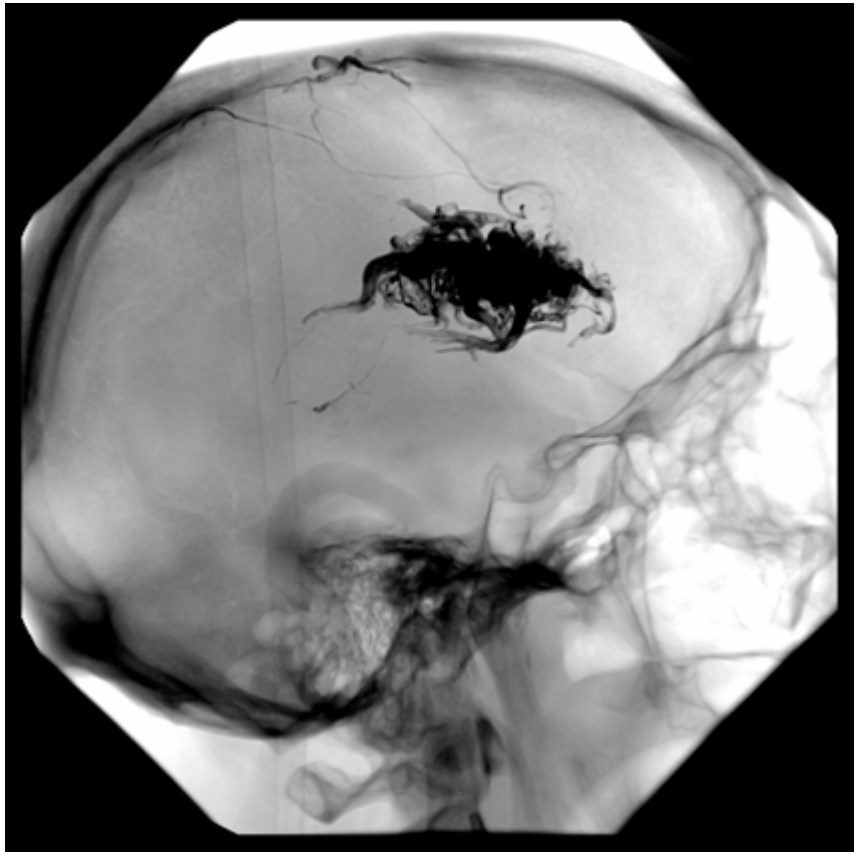

Angioarchitecture

- Compact
- Macrofistula
  - Balloon & Histoacryl
  - Coils & Onyx
- En passant feeder
- Diffuse

Macrofistula : Histoacryl +/- Balloon

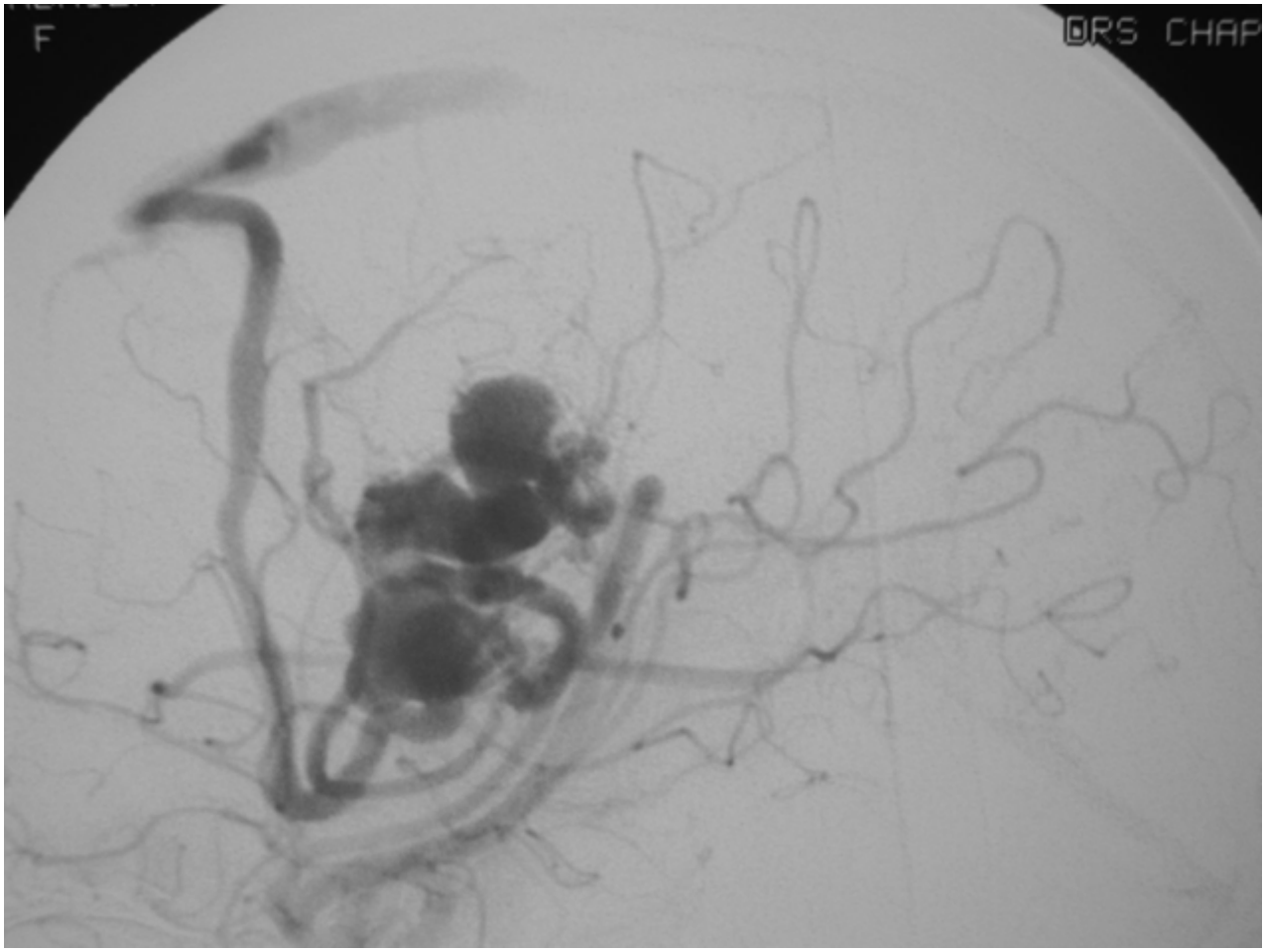

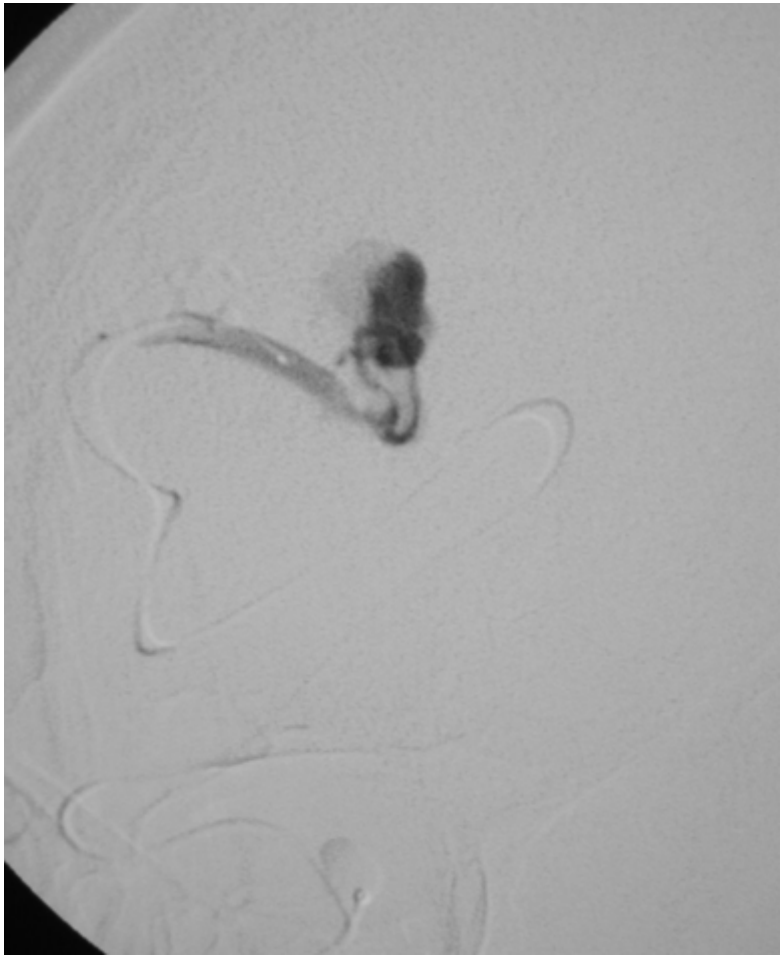

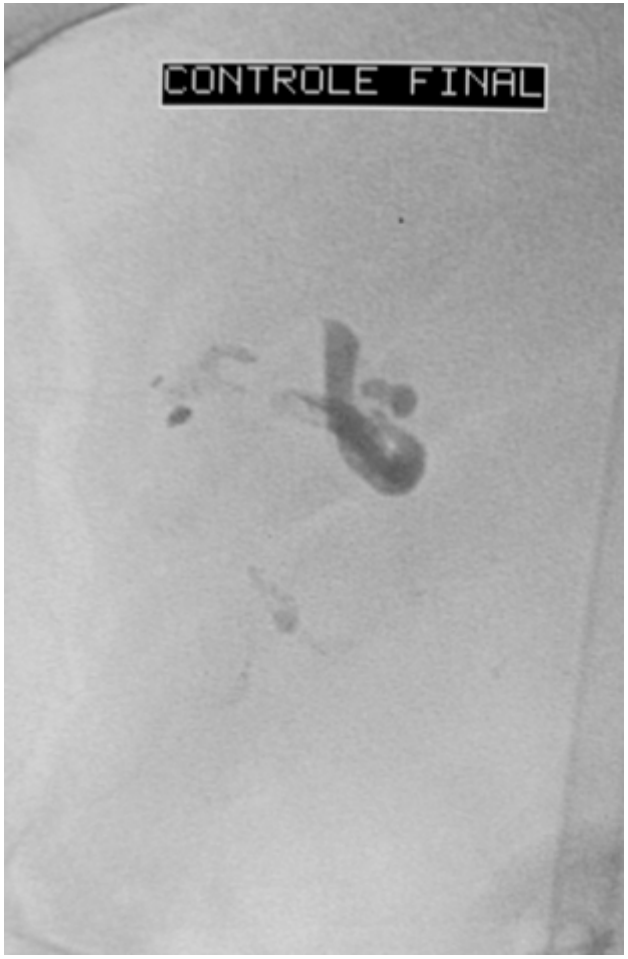
CONTROLE FINAL

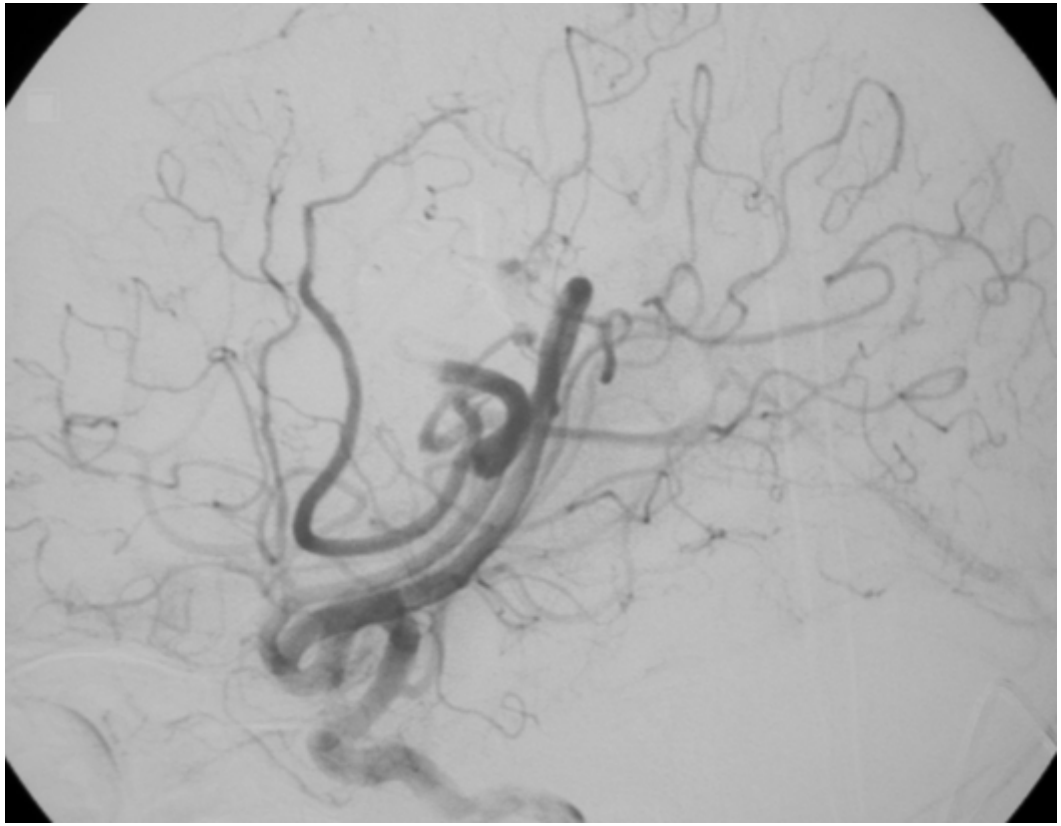

Angioarchitecture

- Compact
- Macrofistula
  - Ballon & Histoacryl
  - Coils & Onyx
- « En passant » feeder
- Diffuse
- Aneurysm

Contraindication :
« En passant » feeder

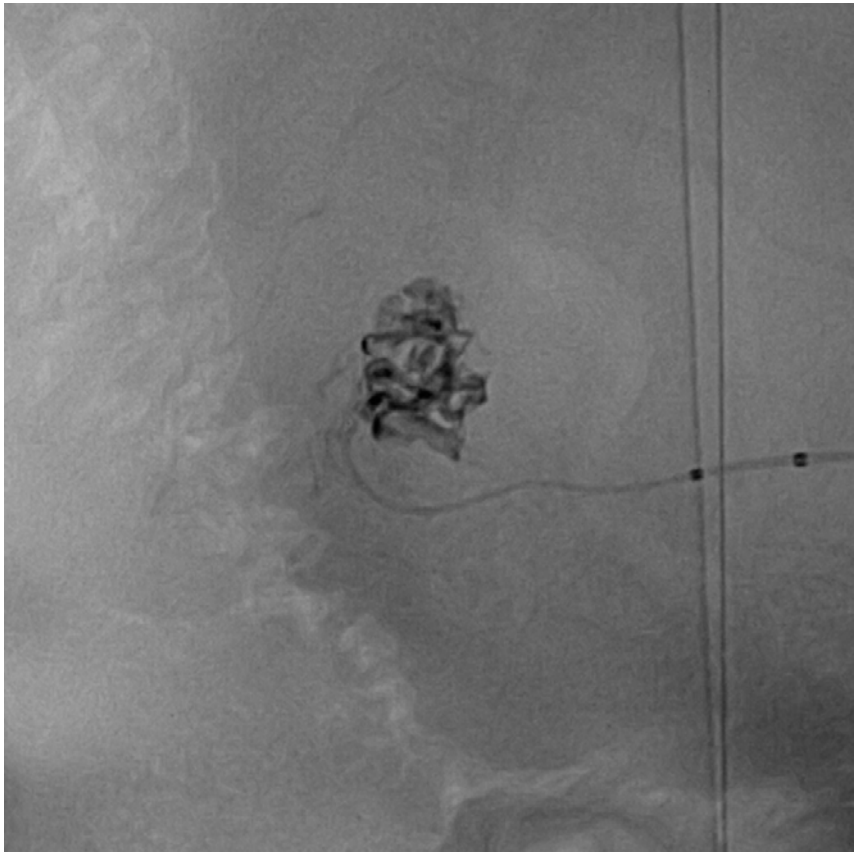

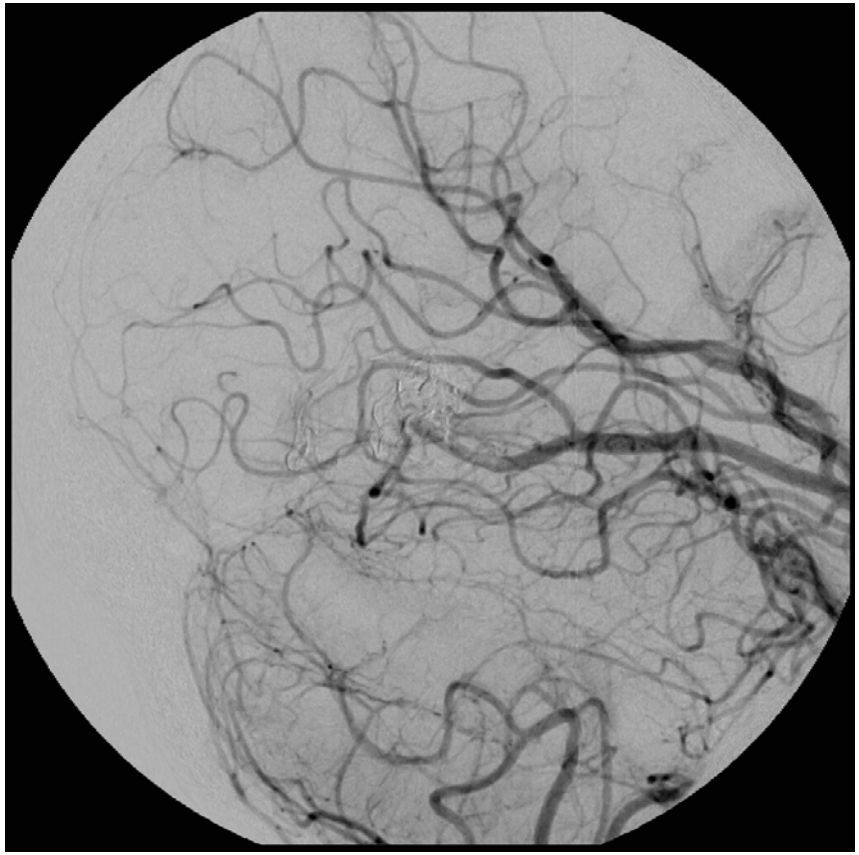

Angioarchitecture

- Compact
- Macrofistula
  - Balloon & Histoacryl
  - Coils & Onyx
- En passant feeder
- Diffuse
- Aneurysm

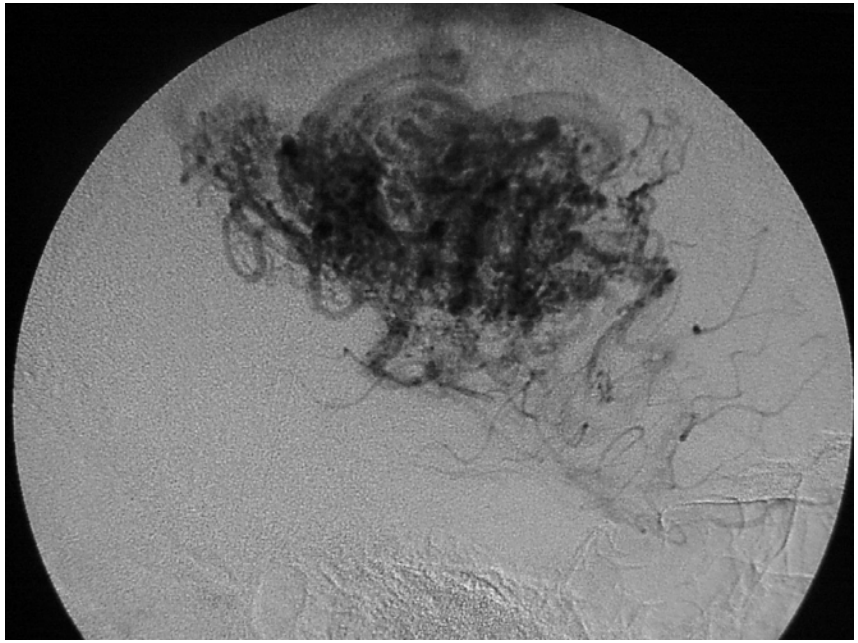

Angioarchitecture

- Compact
- Macrofistula
  - Balloon & Histoacryl
  - Coils & Onyx
- En passant feeder
- Diffuse
- Aneurysm

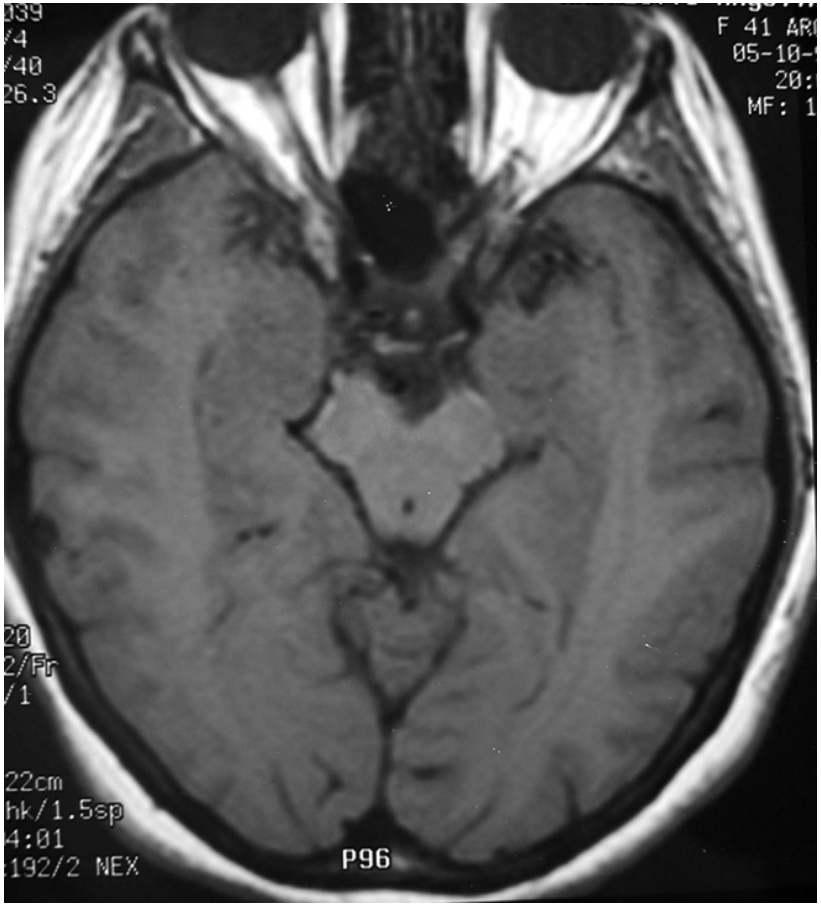
F 41 AR
05-10-
20:
MF: 1
22cm
hk/1.5sp
4:01
192/2 NEX
P96

180

CDE DTE

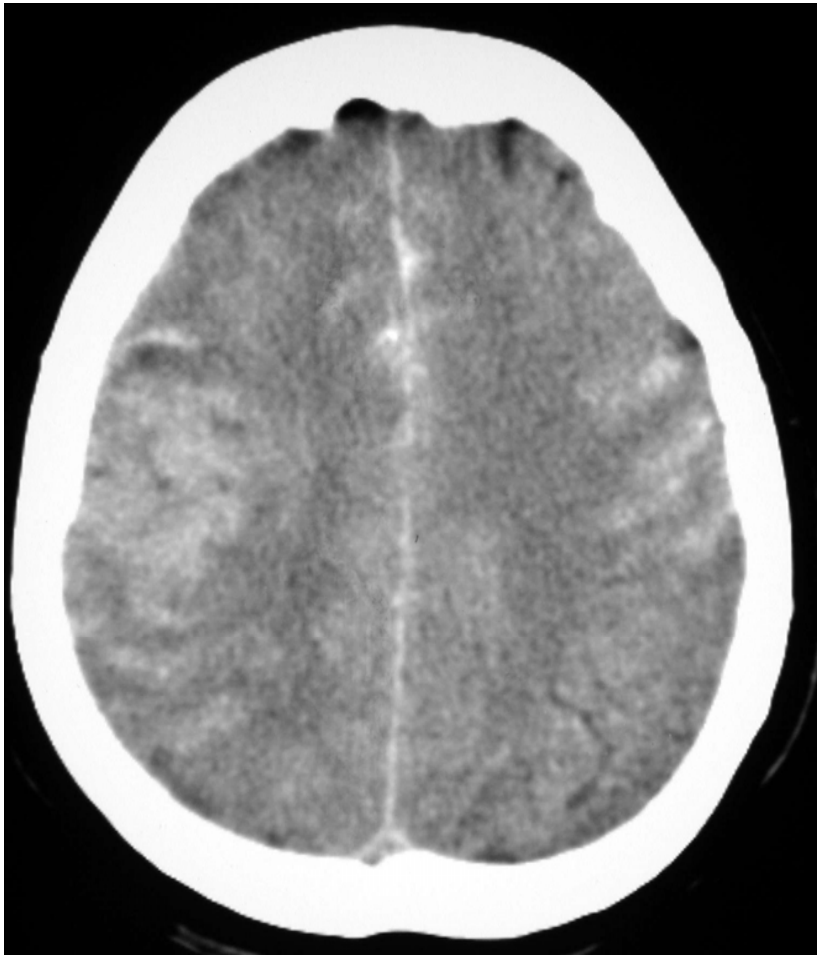

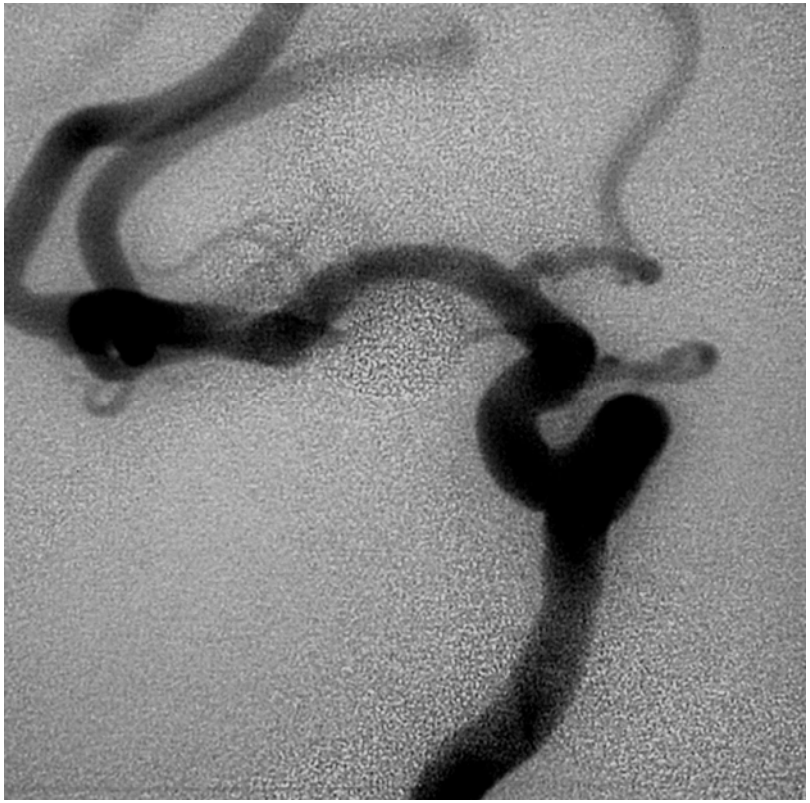

Accessibility

- Small vessels :
  Distal Navigation => Magic 1,2F & NBCA
- Thalamostriates
  => Magic 1,2F & NBCA

- Not accessible vessels => Onyx
  - Cortical Anastomosis
  - Meningeal Feeders
  - Venous approach

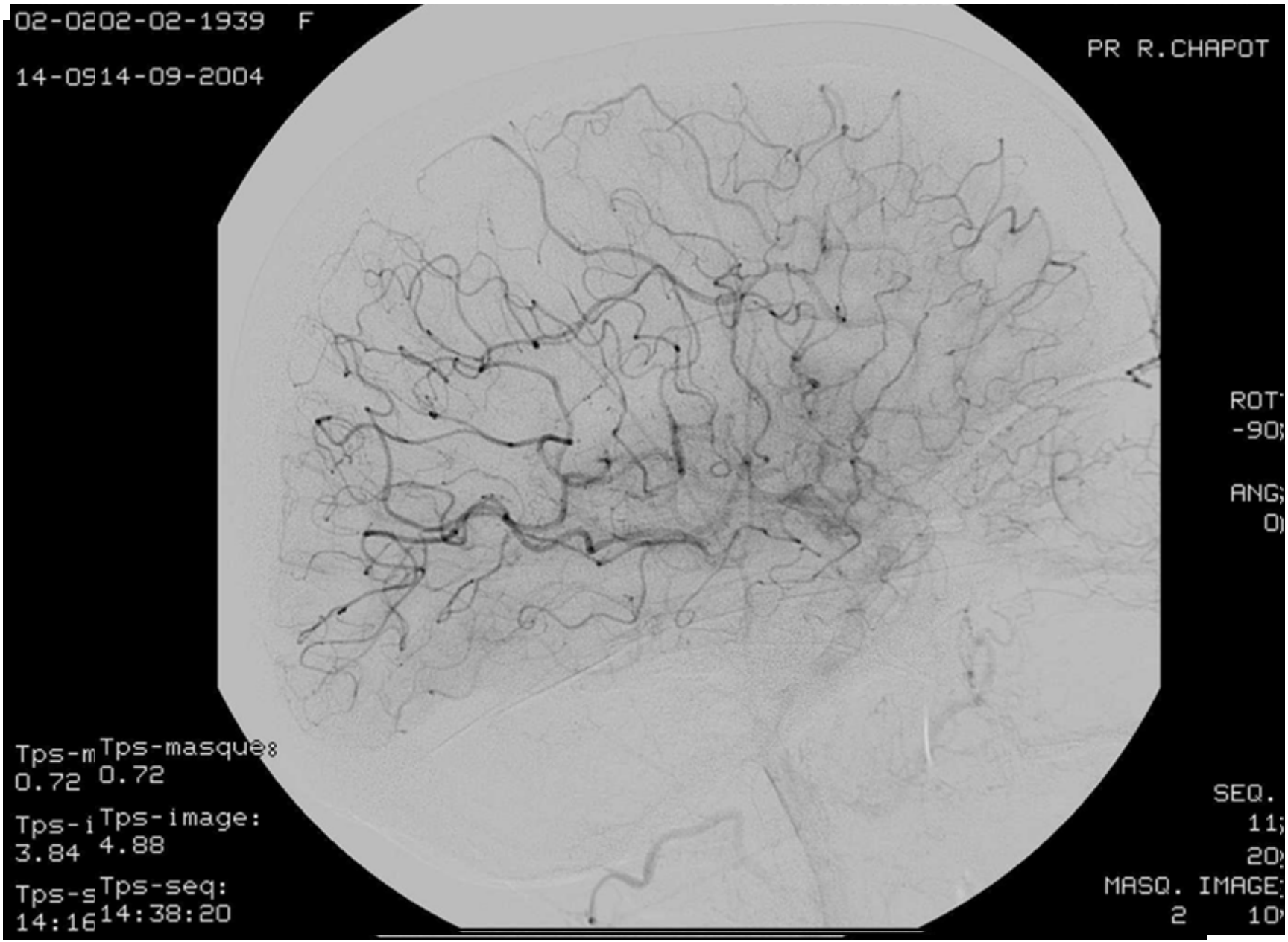
02-0202-02-1939 F
14-0914-09-2004
PR R.CHAPOT
ROT
-90
ANG
0
Tps-m
0.72
Tps-masque:
0.72
Tps-i
3.84
Tps-image:
4.88
Tps-s
14:16
Tps-seq:
14:38:20
SEQ.
11
20
MASQ. IMAGE
2
10

Accessibility

- Small vessels :
  Distal Navigation => Magic 1,2F & NBCA
- Thalamostriates
  => Magic 1,2F & NBCA

- Not accessible vessels => Onyx
  - Cortical Anastomosis
  - Meningeal Feeders
  - Venous approach

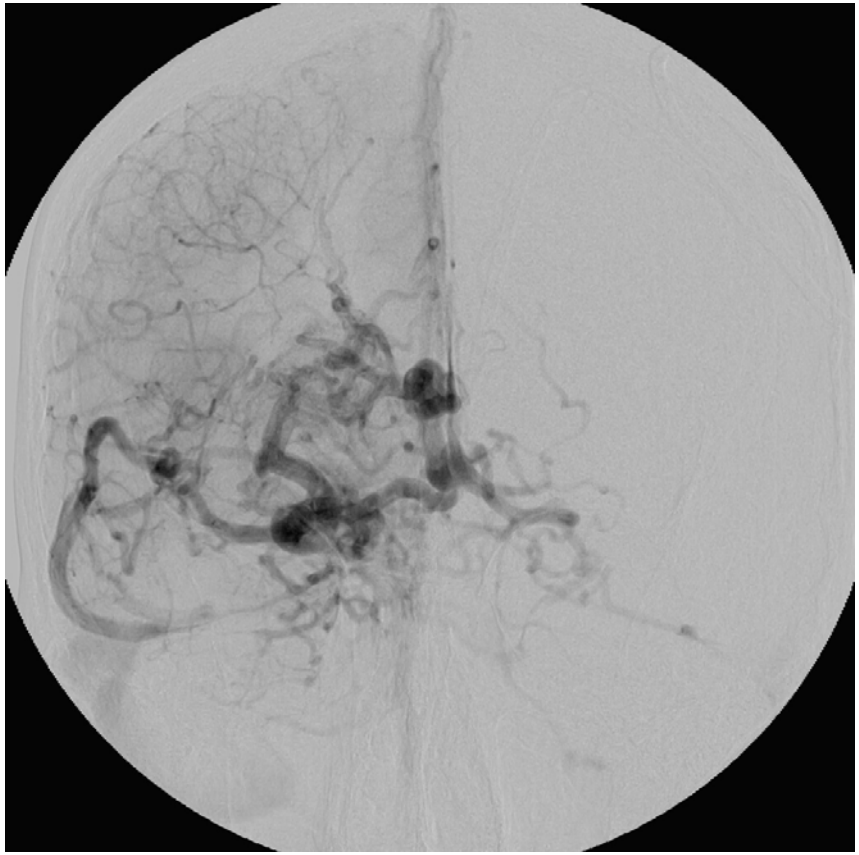

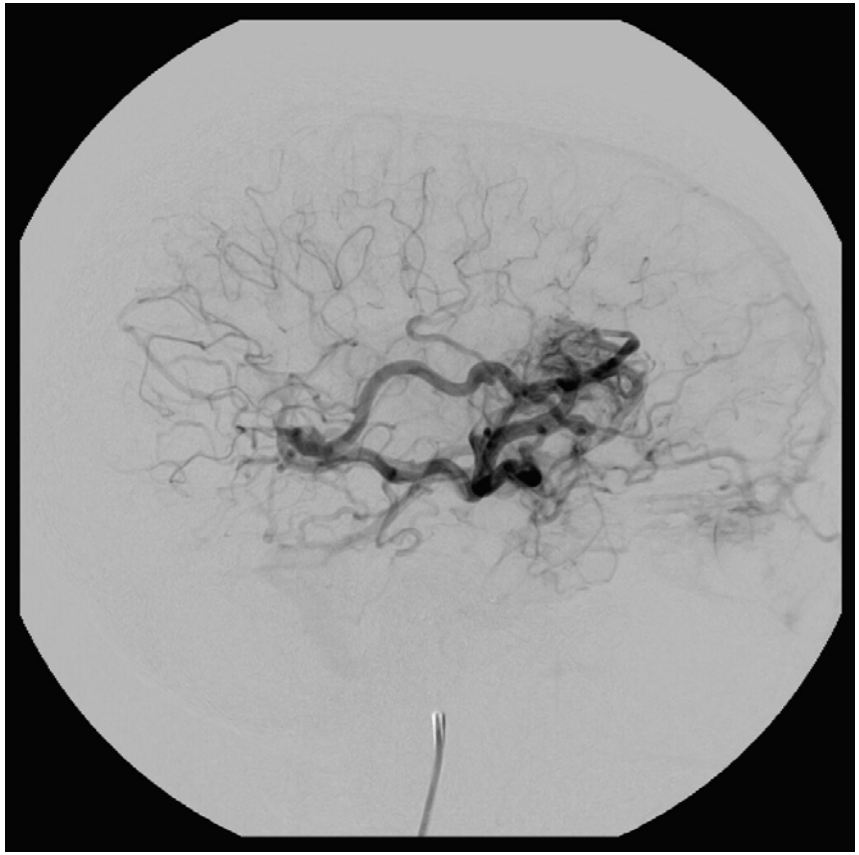

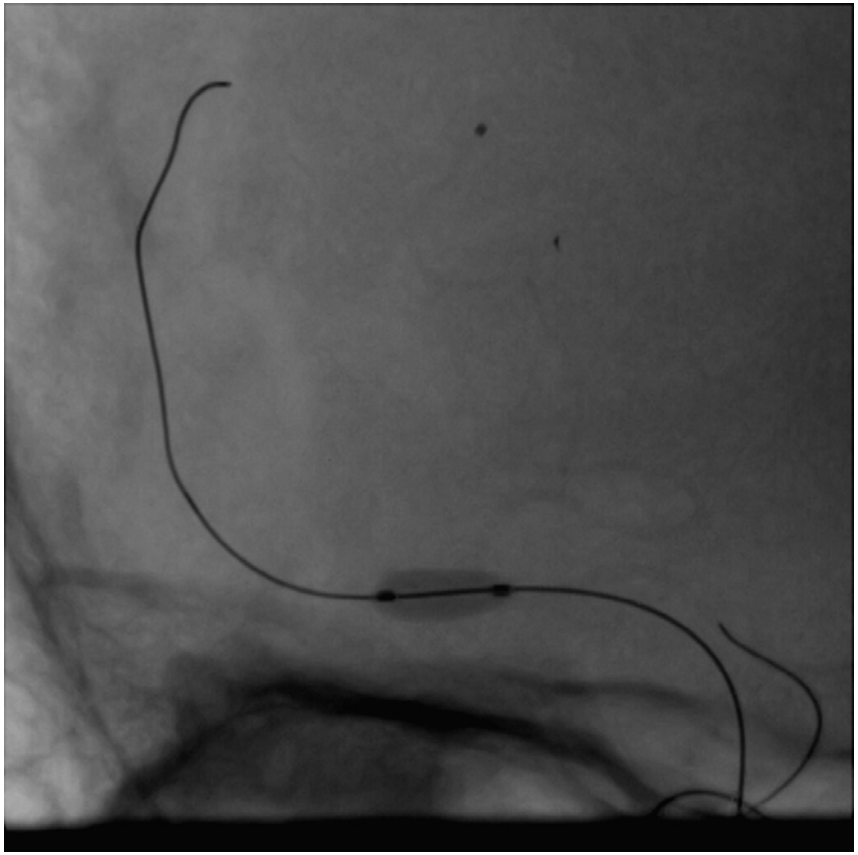

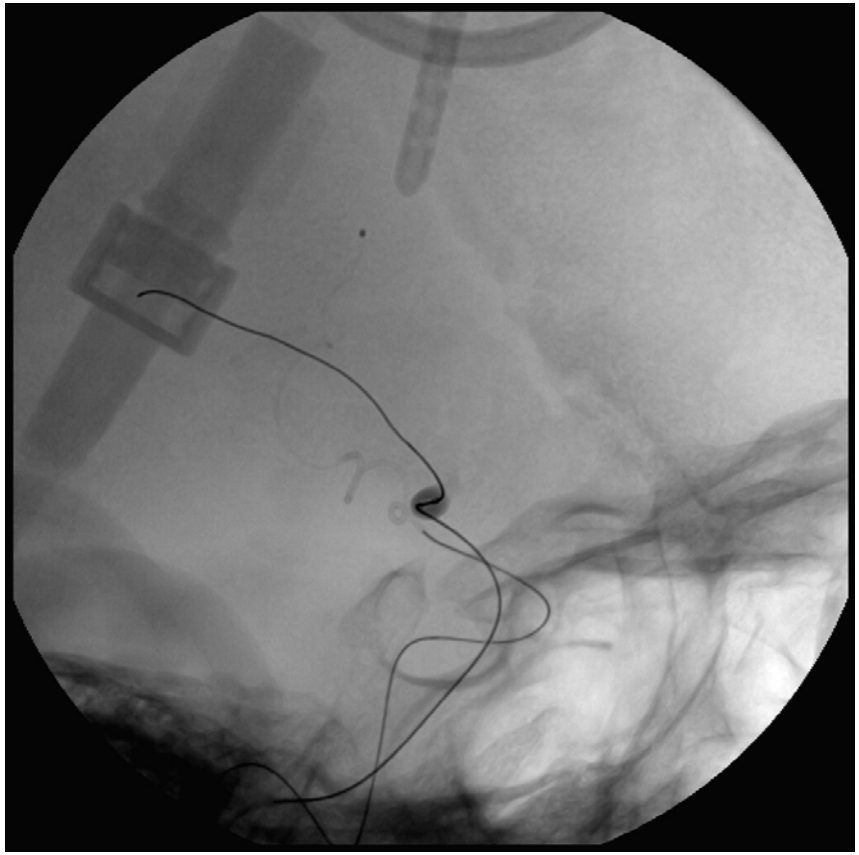

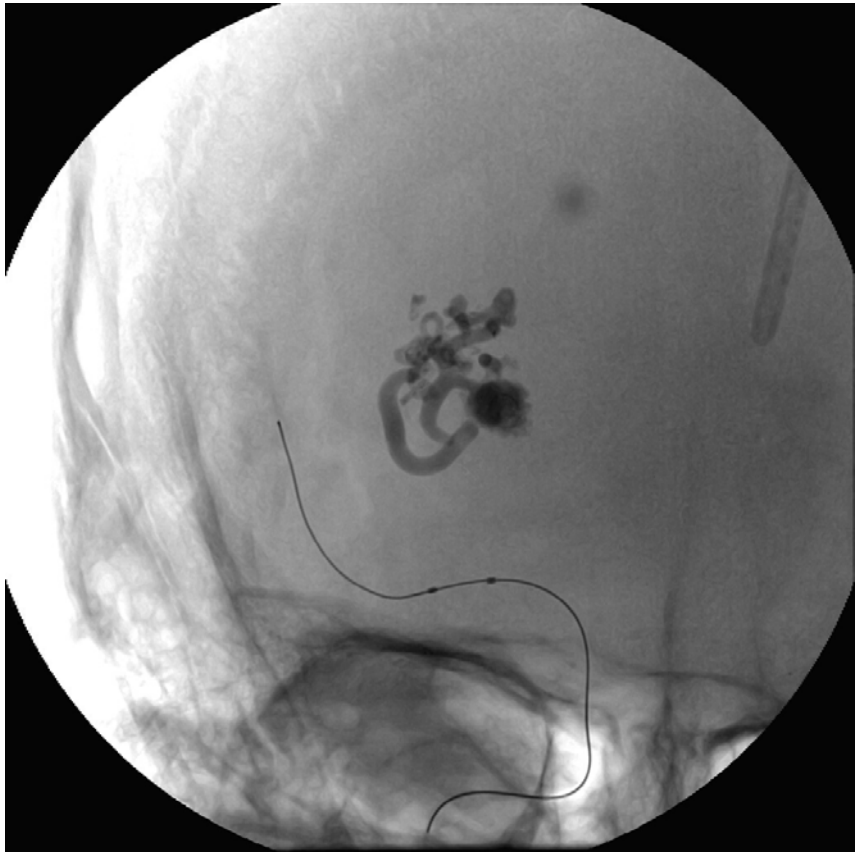

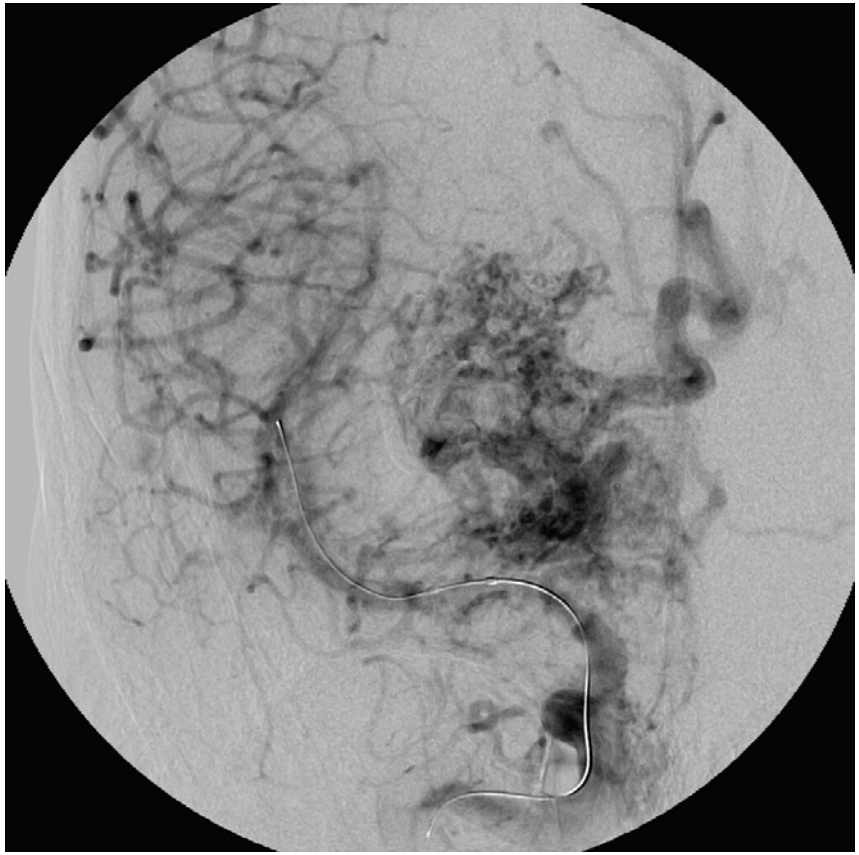

Accessibility

- Small vessels :
  Distal Navigation => Magic 1,2F & NBCA
- Thalamostriates
  => Magic 1,2F & NBCA
  => Sonic & Onyx

- Not accessible vessels => Onyx
  - Cortical Anastomosis
  - Meningeal Feeders
  - Venous approach

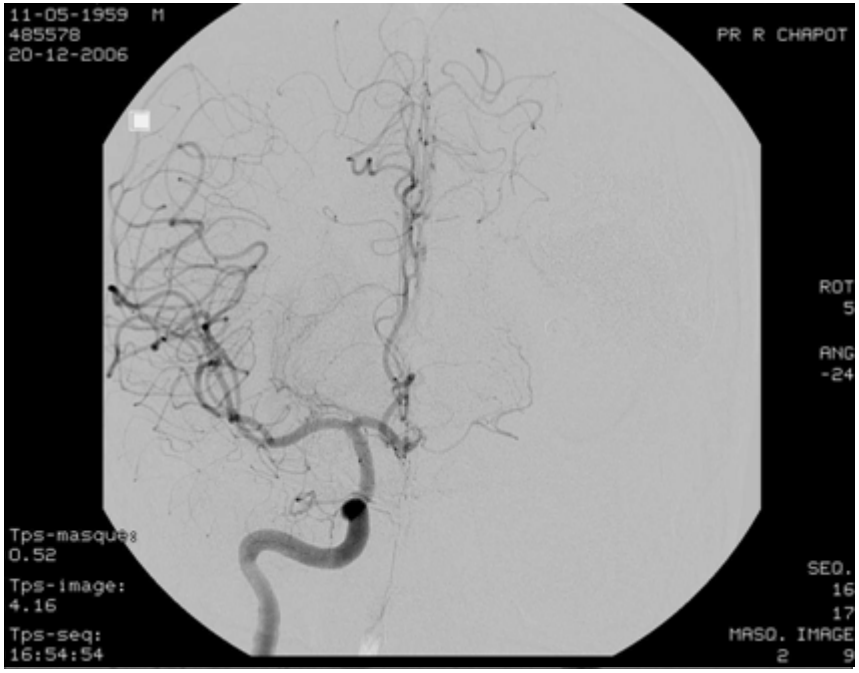
11-05-1959 M
485578
20-12-2006
PR R CHAPOT
ROT
5
ANG
-24
Tps-masque
0.52
Tps-image:
4.16
Tps-seq:
16:54:54
SEQ.
16
17
MASQ. IMAGE
2 9

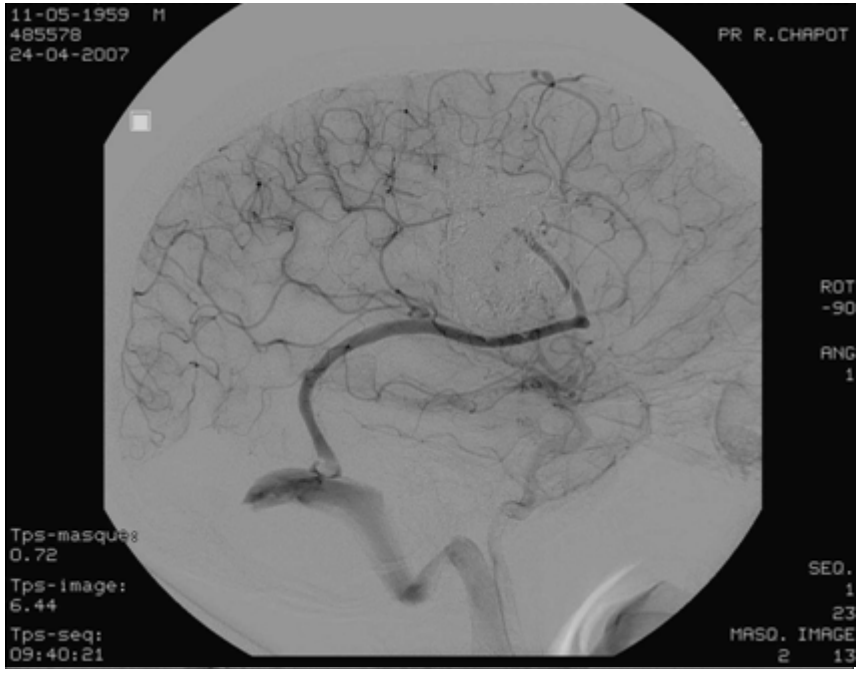
11-05-1959 M
485578
24-04-2007
PR R.CHAPOT
ROT
-90
ANG
1
Tps-masque
0.72
Tps-image:
6.44
Tps-seq:
09:40:21
SEQ.
1
23
MASQ. IMAGE
2 13

Accessibility

- Small vessels :
  Distal Navigation => Magic 1,2F & NBCA
- Thalamostriates
  => Magic 1,2F & NBCA

- Not accessible vessels => Onyx
  - Cortical Anastomosis
  - Meningeal Feeders
  - Venous approach

TAEUBER,ANJA
0002050695
22.10.66
M: 3/1
I: 12/1
3/200
6-MAY-02
10:56:16
Phys:
W-B: 190
W-C: 120
9
A. Krupp
ICA L pa

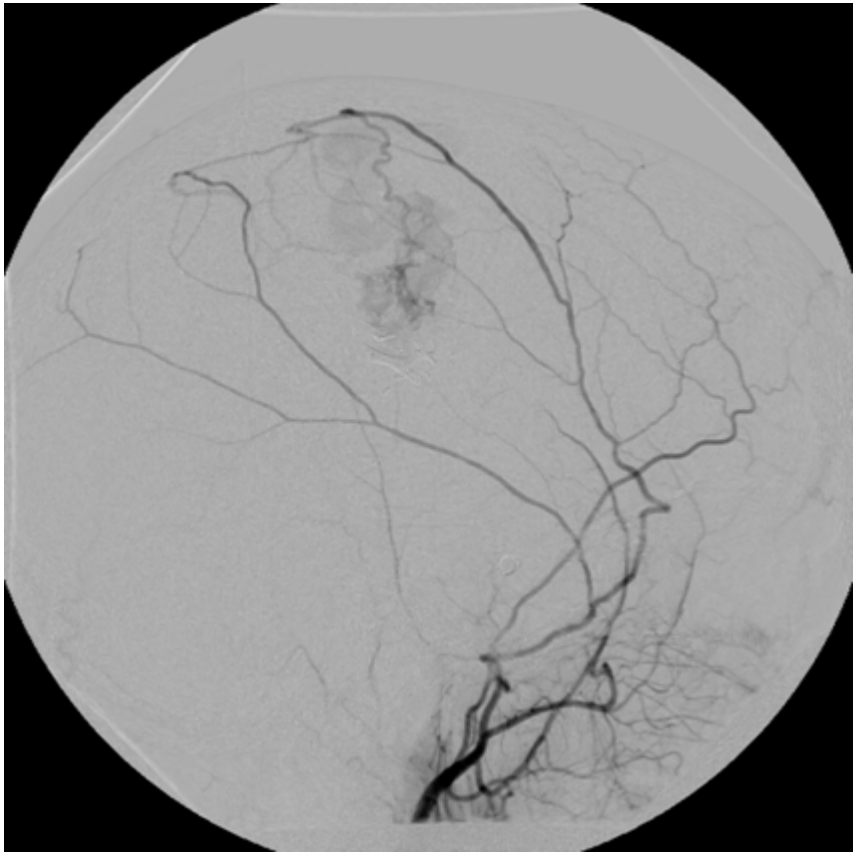

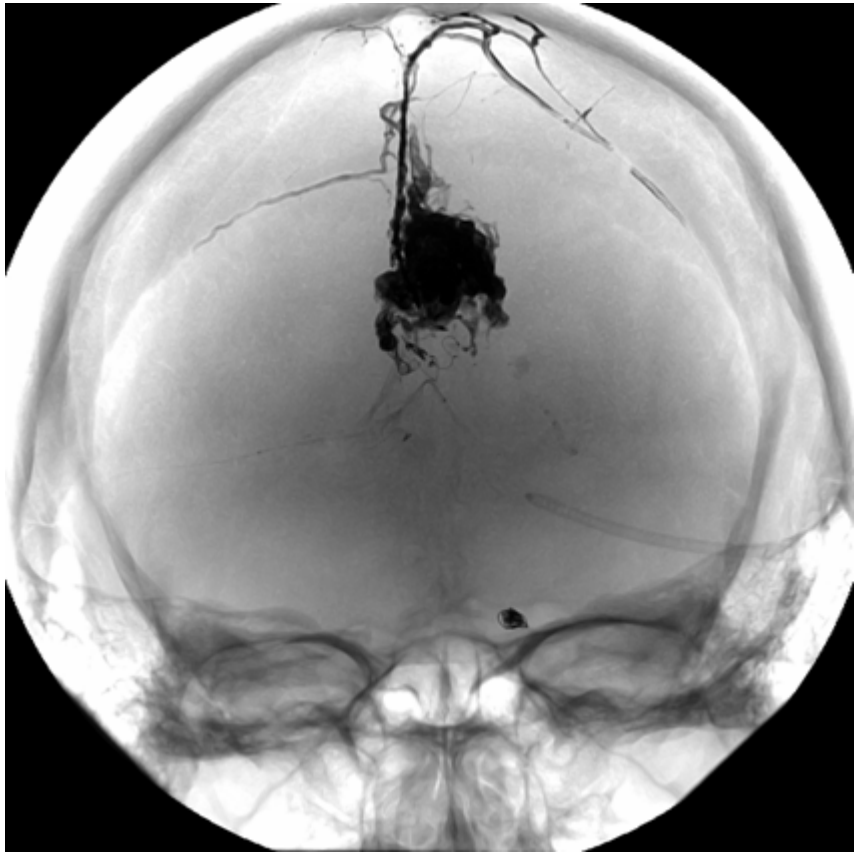

Accessibility

- Small vessels :
  Distal Navigation => Magic 1,2F & NBCA
- Thalamostriates
  => Magic 1,2F & NBCA

- Not accessible vessels => Onyx
  - Cortical Anastomosis
  - Meningeal Feeders
  - Venous approach

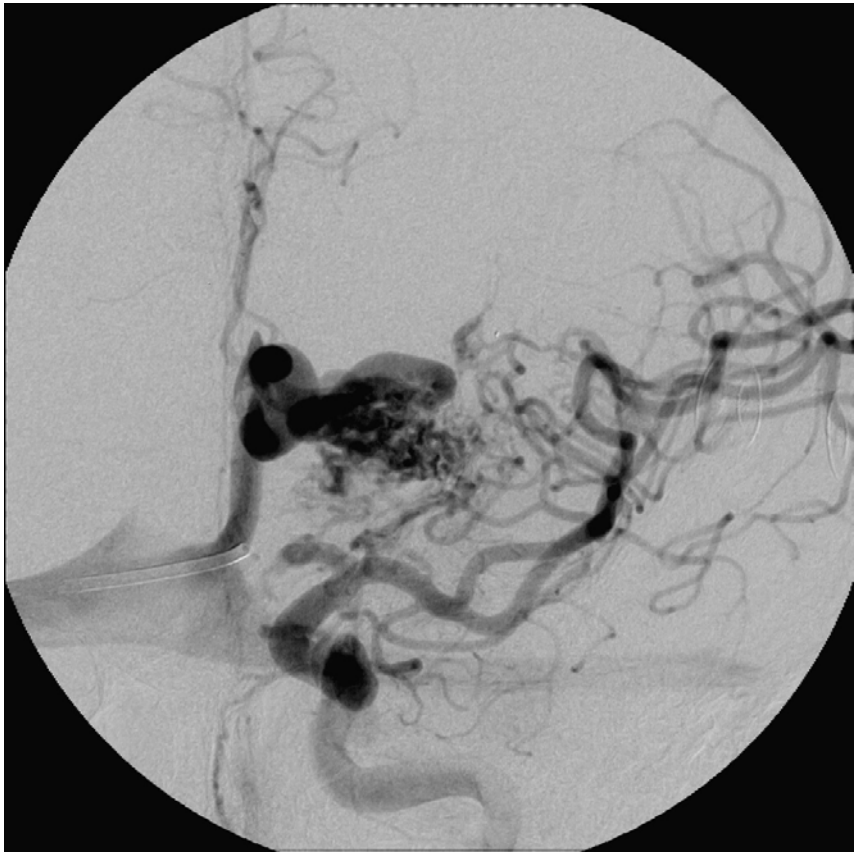

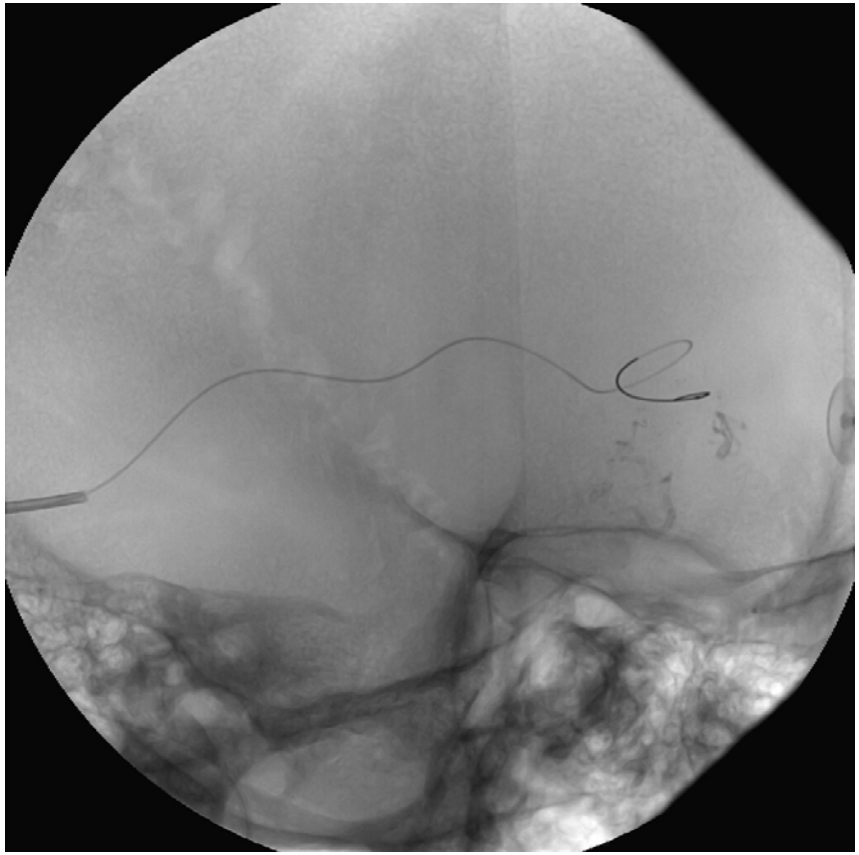

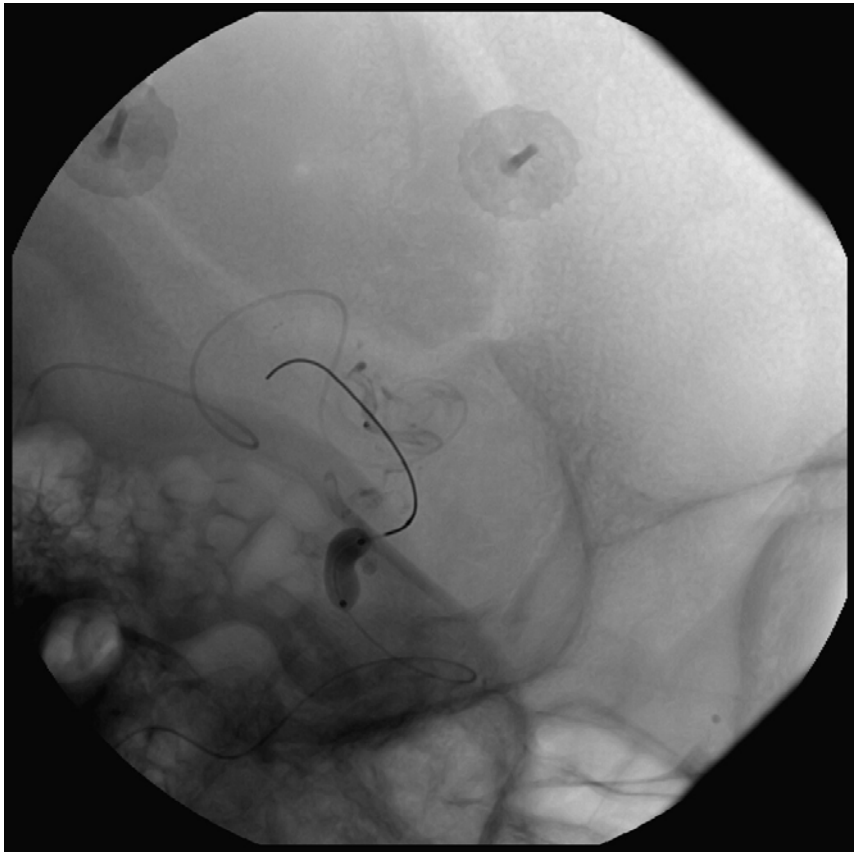

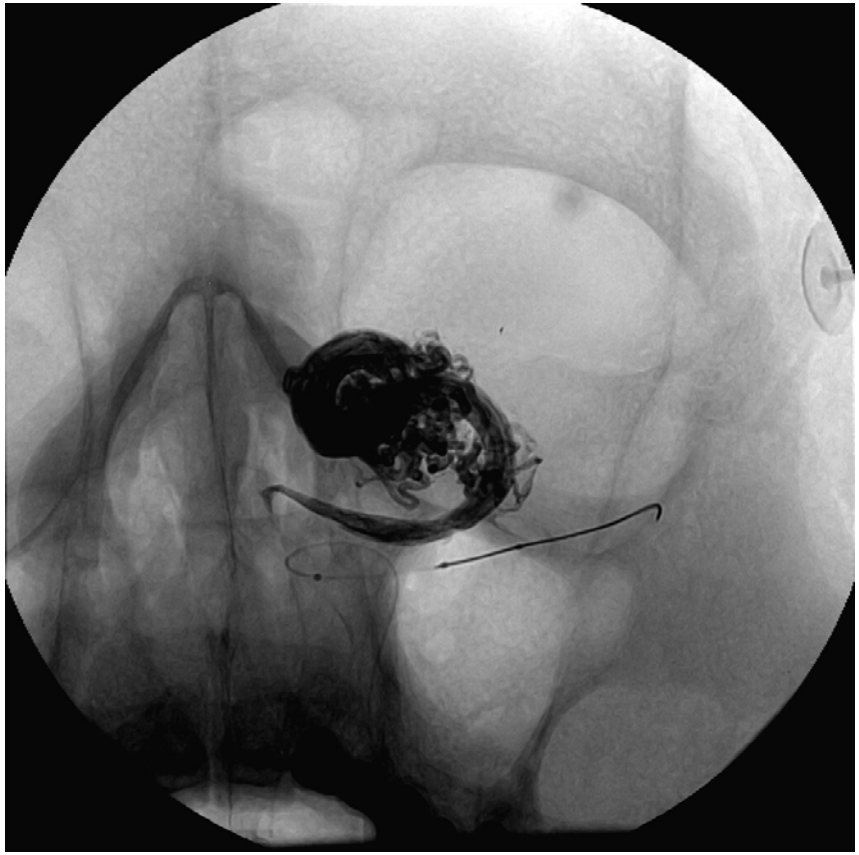

Drawbacks Onyx

- Increased ischemic risk

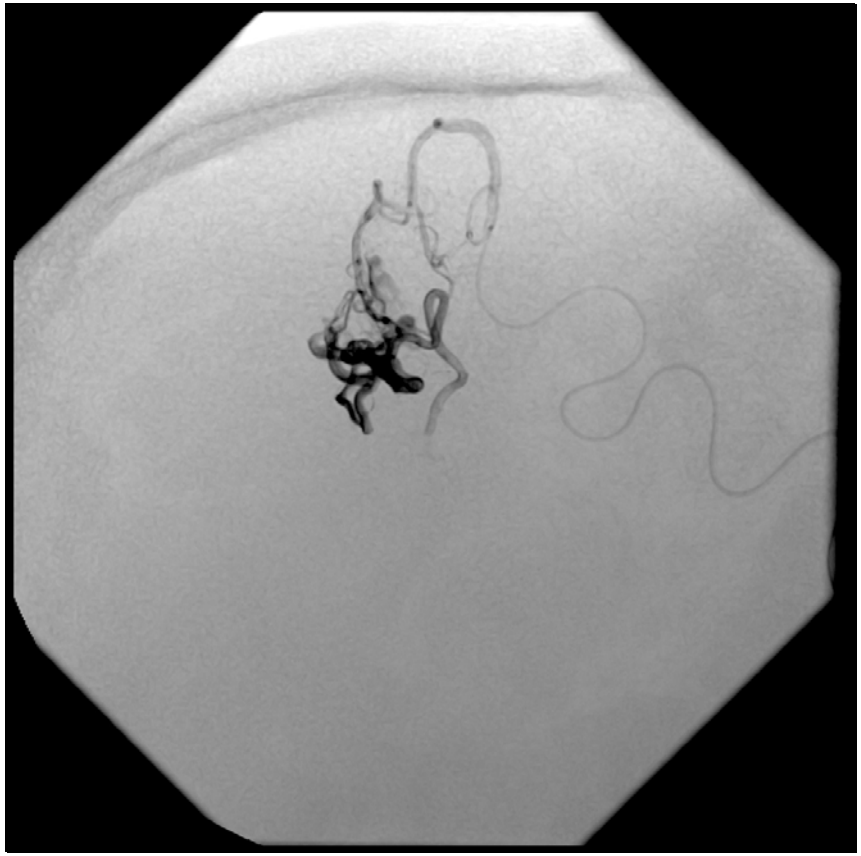

Drawbacks Onyx

- Increased ischemic risk : reduced by
  - Biplane
  - Understanding of embolized structures
  - Intranidal position of microcatheter = centrifugal diffusion at tip of microcatheter

- High amount of embolising agent => No visibility !

Drawbacks Onyx

- Increased ischemic risk

- High amount of embolising agent => No visibility !
  - Change working projection
  - How much Onyx?
  - How many sessions?

Complications

- Bleeding
  - Occlusion of main draining vein
  - Retrieval of Microcatheter
- Ischemia
  - Occlusion of normal vessels
  - Retrograde thrombosis of feeders
- Inadequate Embolisation

Complications

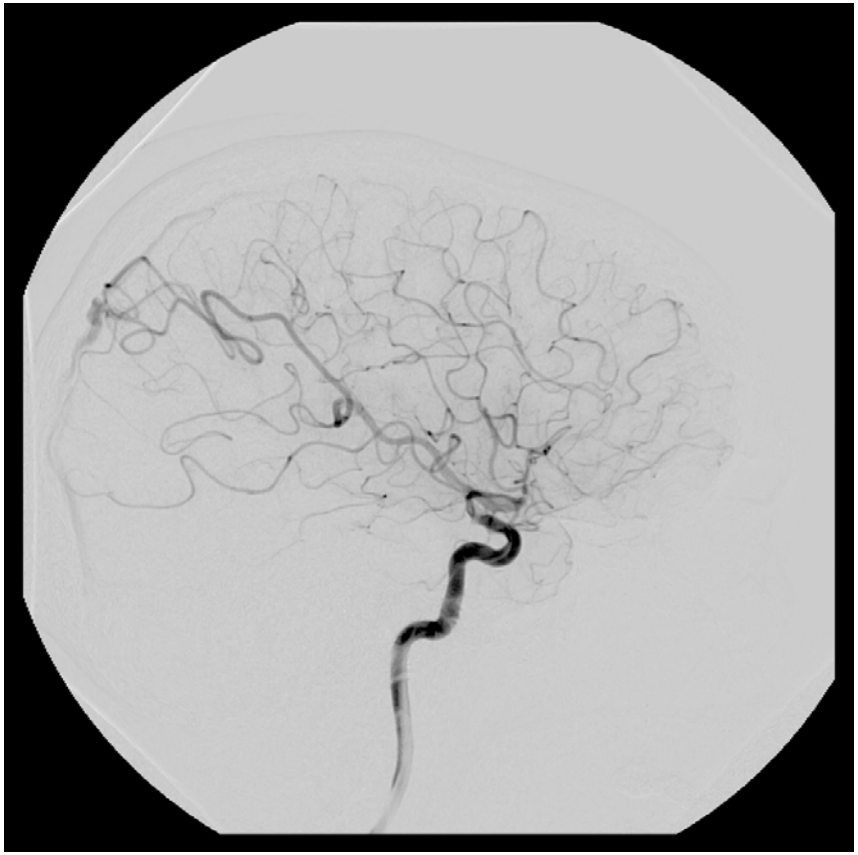

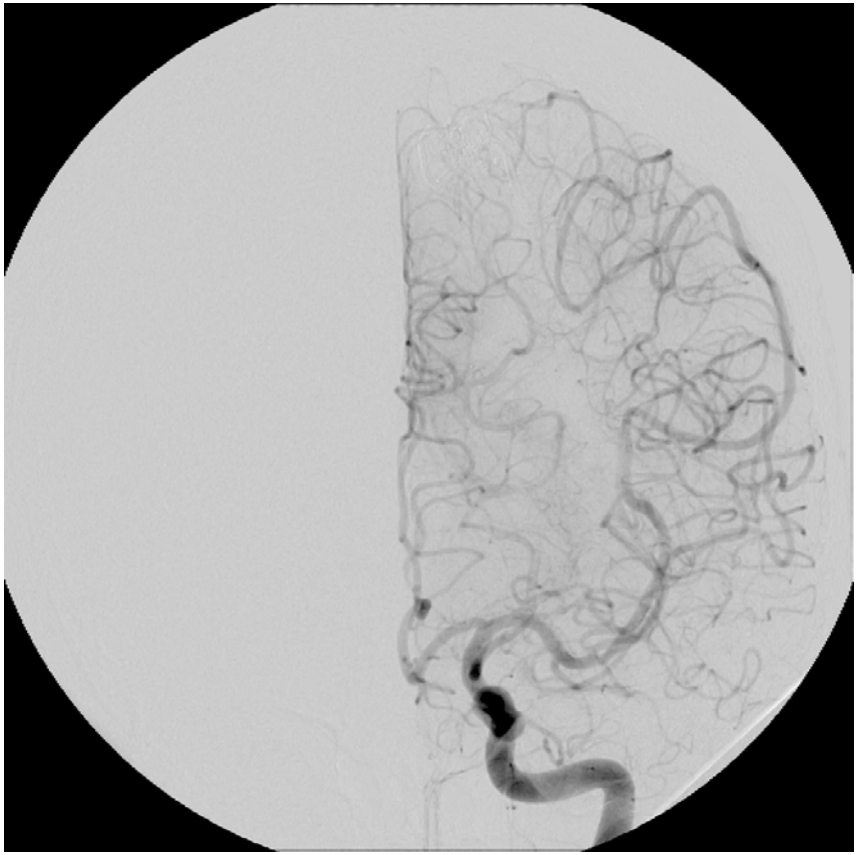

Complications

- Bleeding
  - Occlusion of main draining vein
  - Retrieval of Microcatheter
  - Intranidal placement of microcatheter tip
- Ischemia
  - Occlusion of normal vessels
  - Retrograde thrombosis of feeders
- Inadequate Embolisation

Occlusion of normal branches

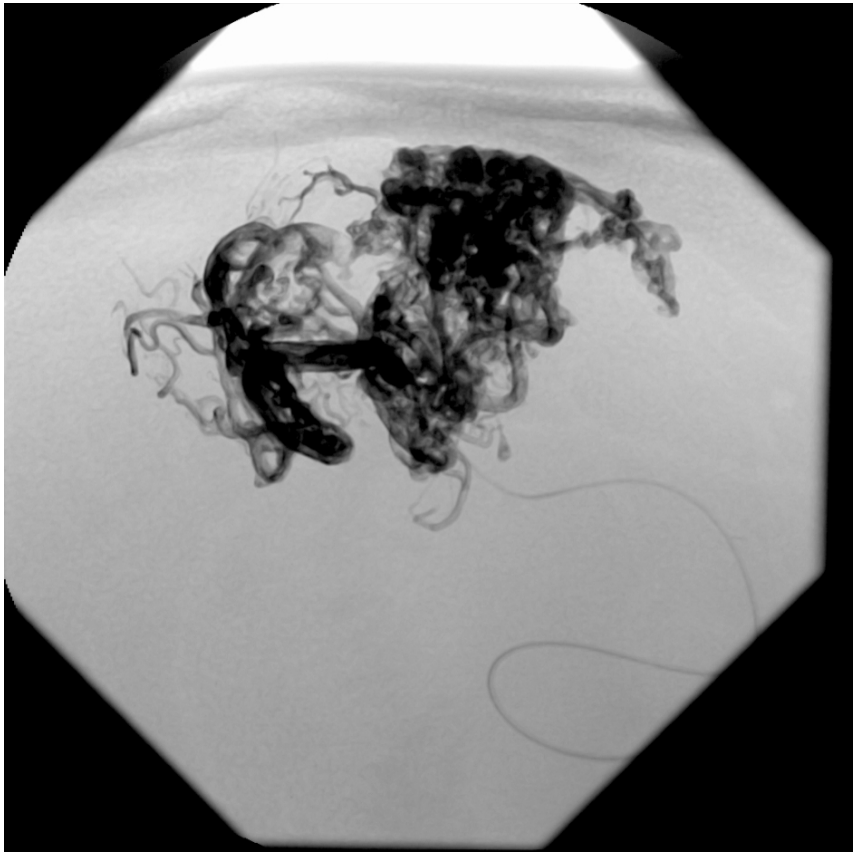

Retrograde Arterial Thrombosis

Complications

- Bleeding
  - Occlusion of main draining vein
  - Retrieval of Microcatheter
  - Catheterization of intranidal vessels
- Ischemia
  - Occlusion of normal vessels
  - Retrograde thrombosis of feeders
- Inadequate Embolisation

Proximal Occlusion



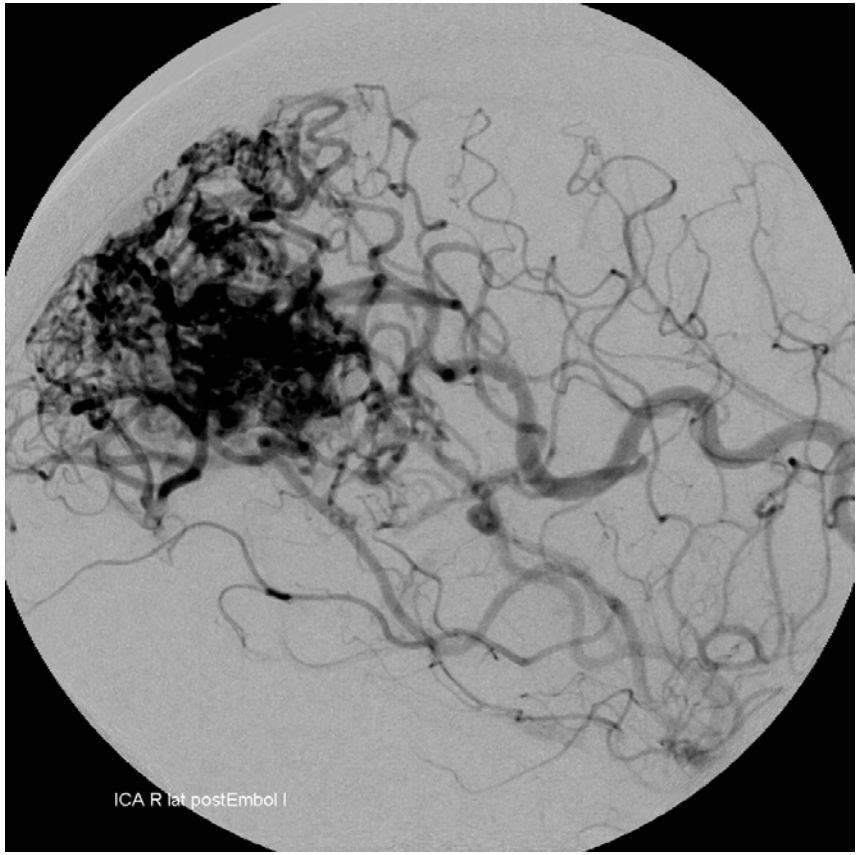

Development of collaterals

Conclusion

- Evolution of endovascular therapy
- Embocure : 50% to 60%
- Surgery & Radiation therapy = Adjuvant Therapies