Saint 2010

6. Symposium für angewandte interventionsradiologische Techniken

Rheingau, 9. - 11. September 2010

Embolisation von Uterusmyomen (UAE)

Technik & Erfolgskontrolle

B. Radeleff, U. Stampfl
Diagnostische und Interventionelle Radiologie Heidelberg

Präinterventionelles Management

- Patienten Vorbereitung und Monitoring
  - intravenöser Zugang
  - EKG
  - Puls-Oxymetrie
  - Blutdruckmessung

  - PCA-Anästhesie: Blasen-DK

UAE Technik I

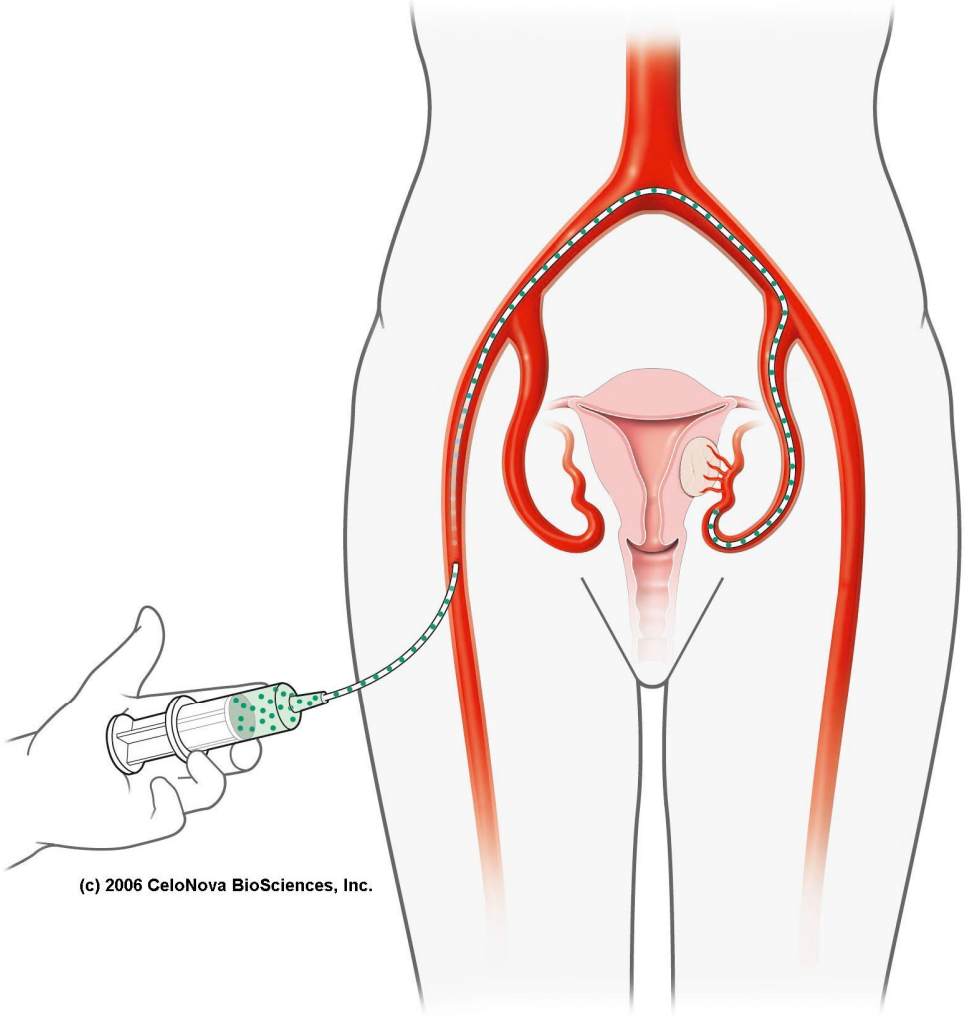

- Unilateraler Zugang
- kurze F4 Schleuse
- F4 Cobra-Katheter
- Terumo-Draht

Ausgangs-MRT

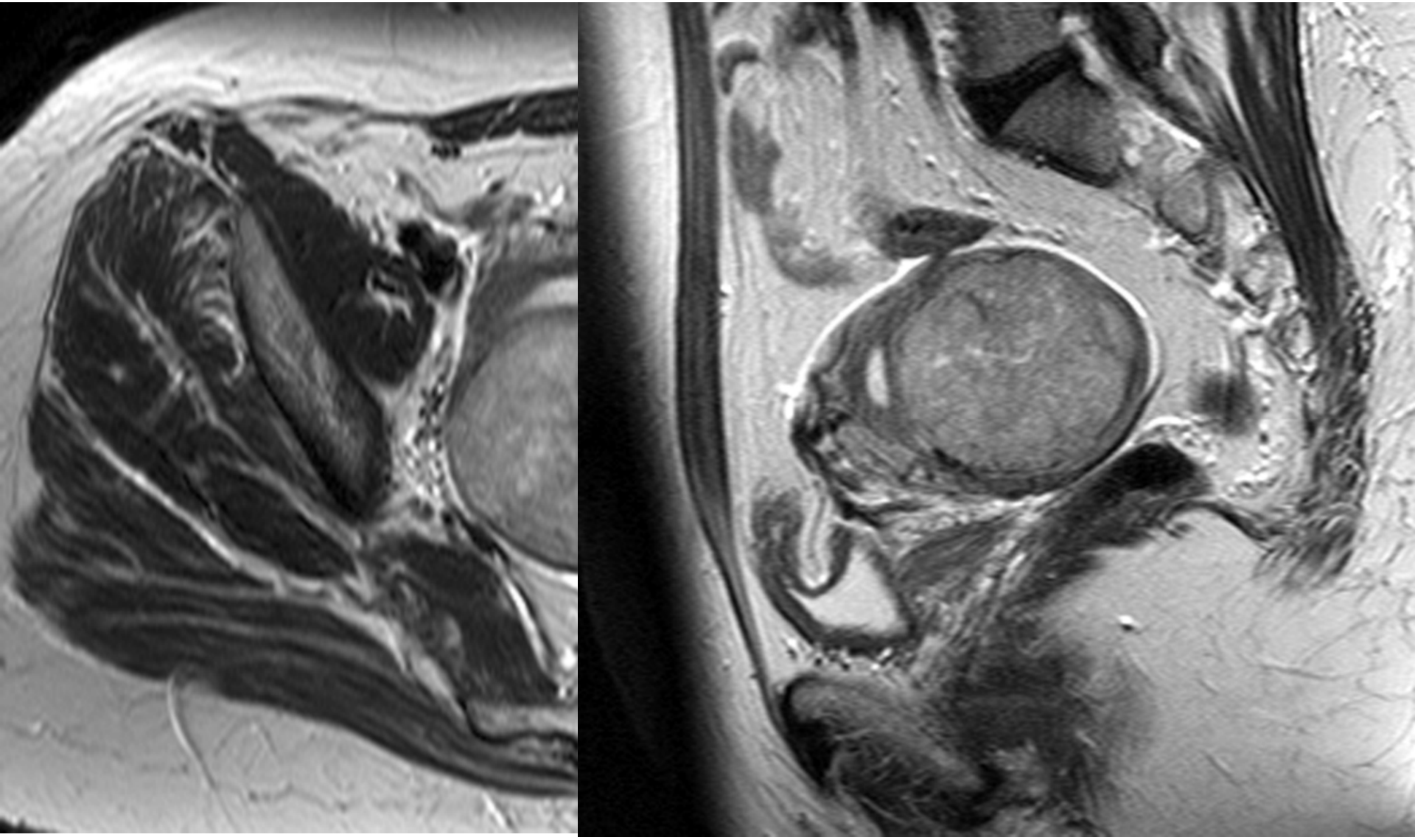

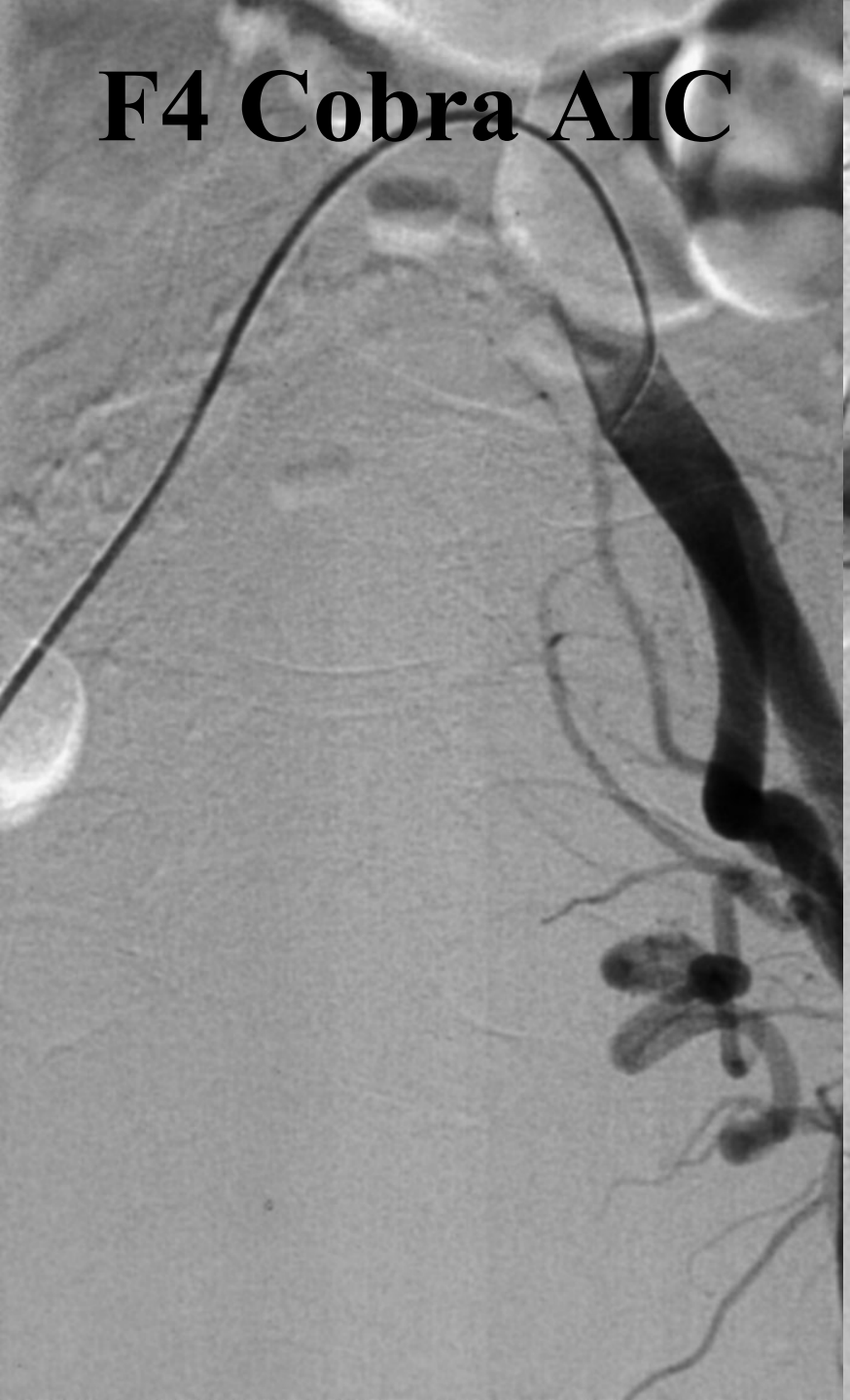
F4 Cobra AIC

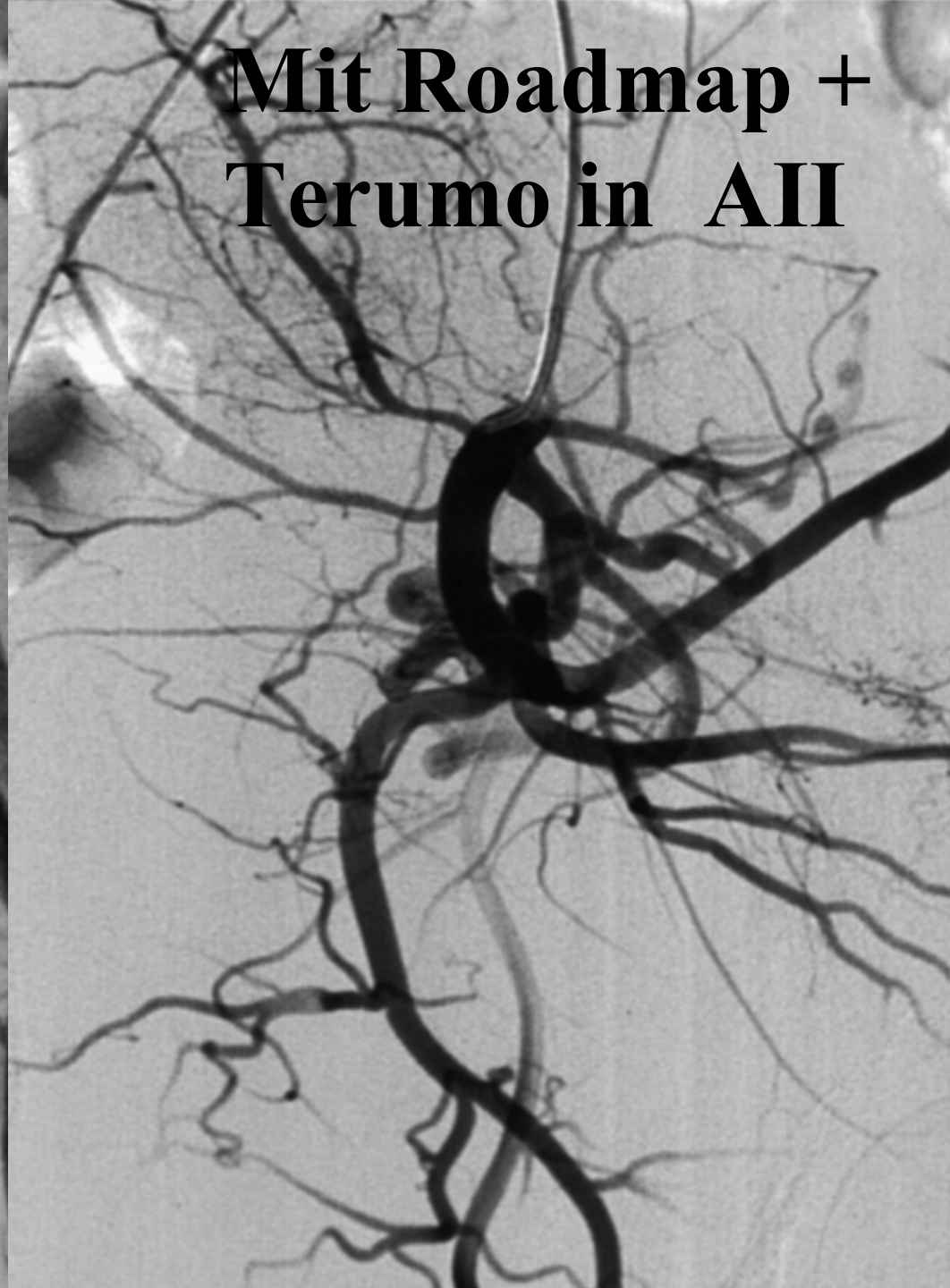
Mit Roadmap +
Terumo in AII

Sondierung linke A. uterina: RAO, 40°

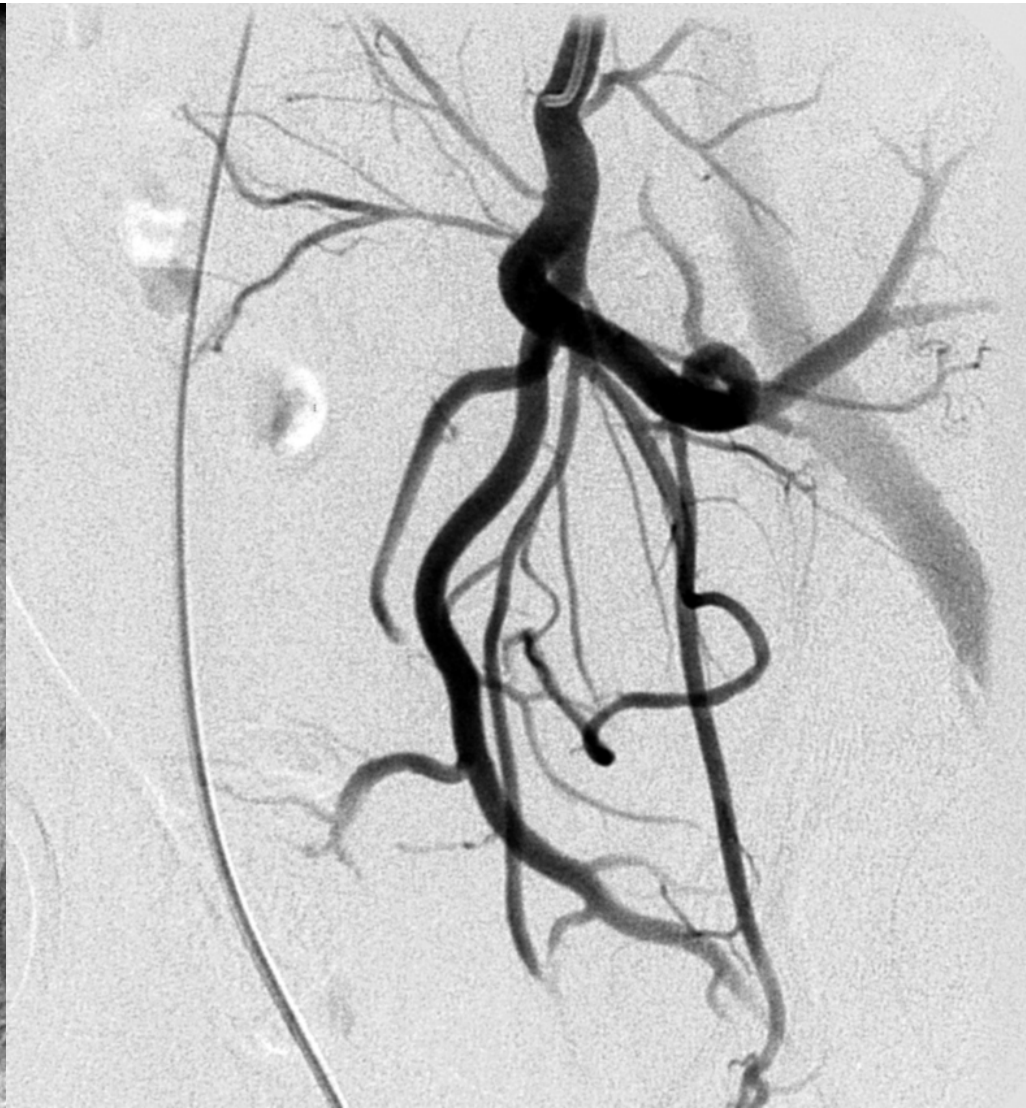

Sondierung linke A. uterina: LAO, 40°

Sondierung linke A. uterina: RAO, 40°

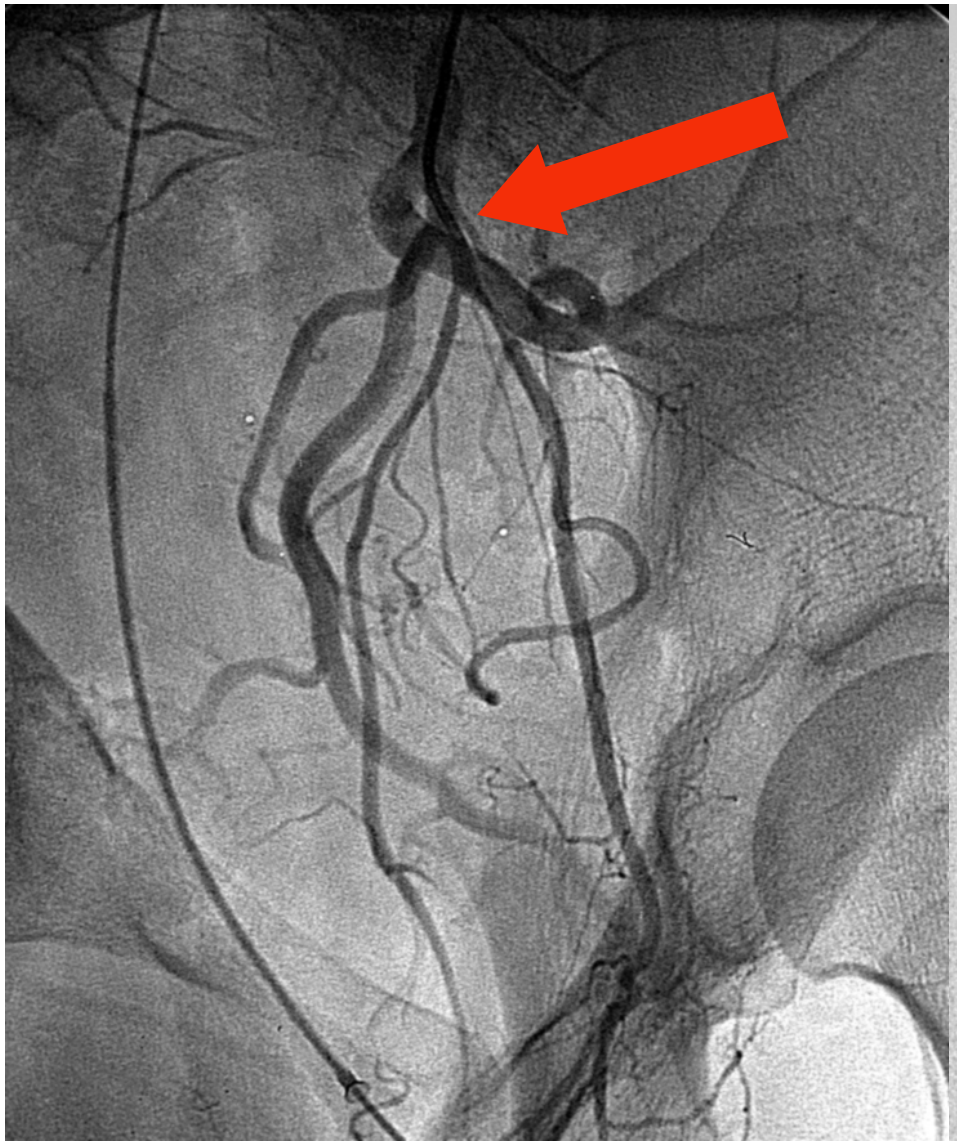

UAE Technik II

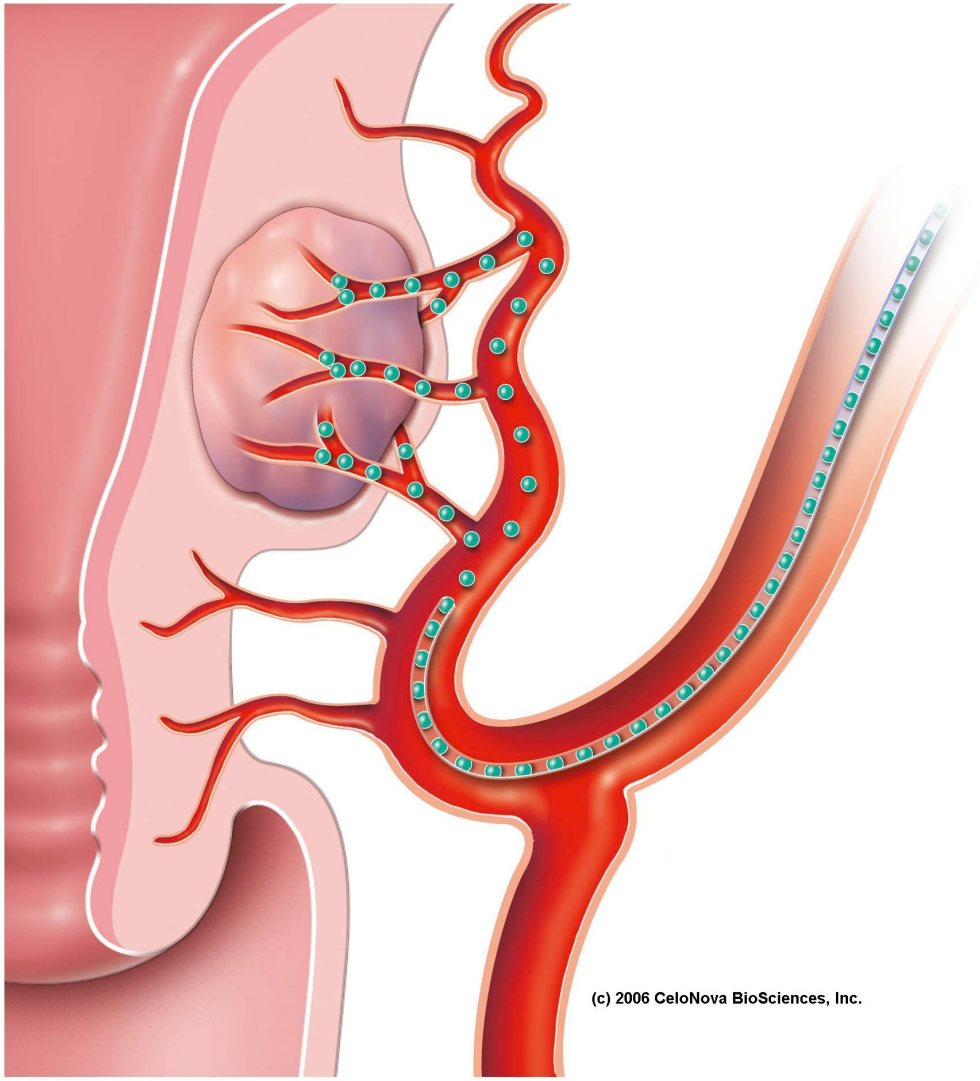

- Mikrokatheter
- Mikro-Position
- Embolisatwahl
- Free Flow

UAE Technik III

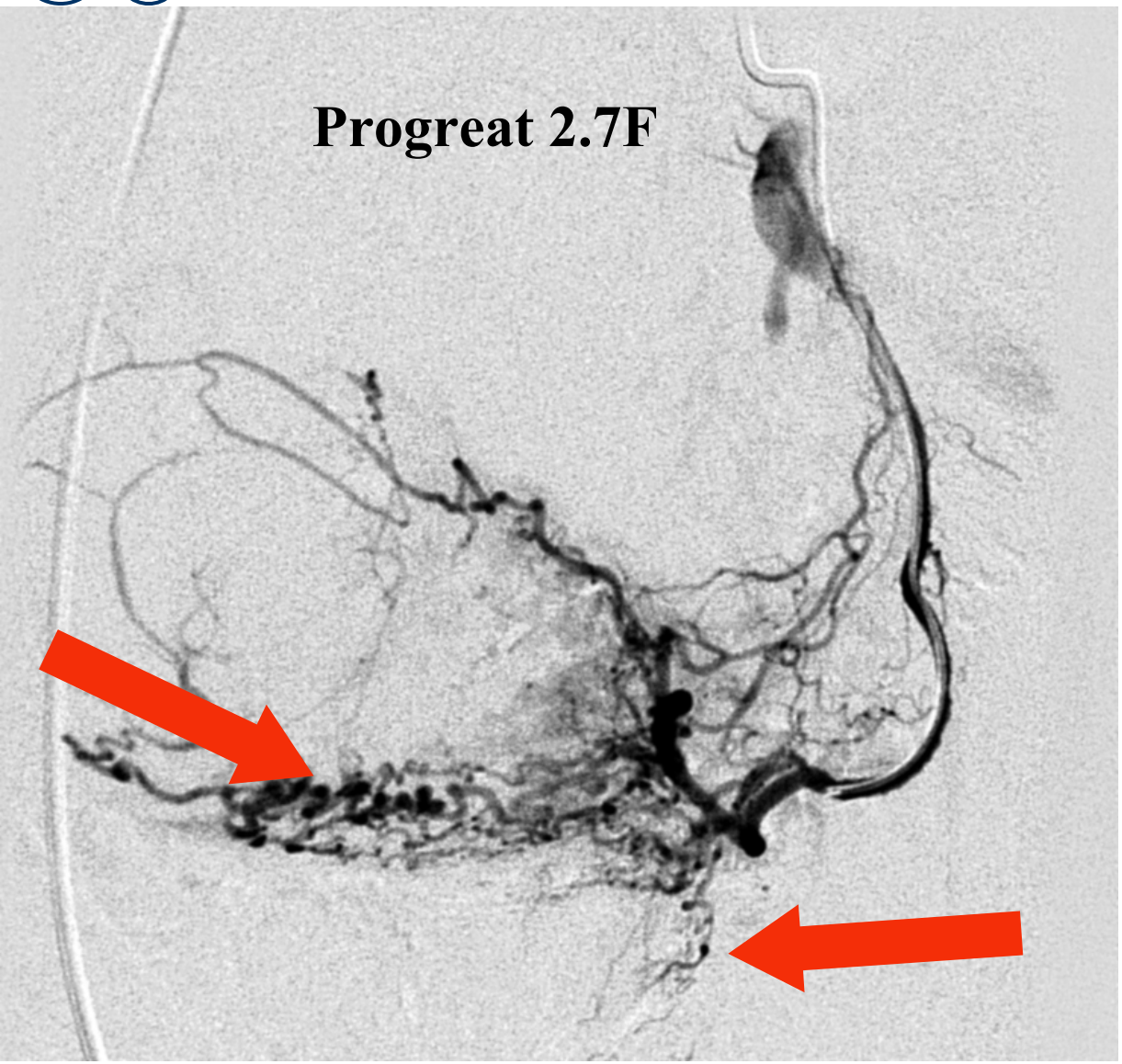

- Mikrokatheter
- Mikro-Position
- Embolisatwahl
- Free Flow

Cave:

- Spasmus
- cervicovag. Äste

Optimale Vorbereitung des Embolisates



Embolisation:

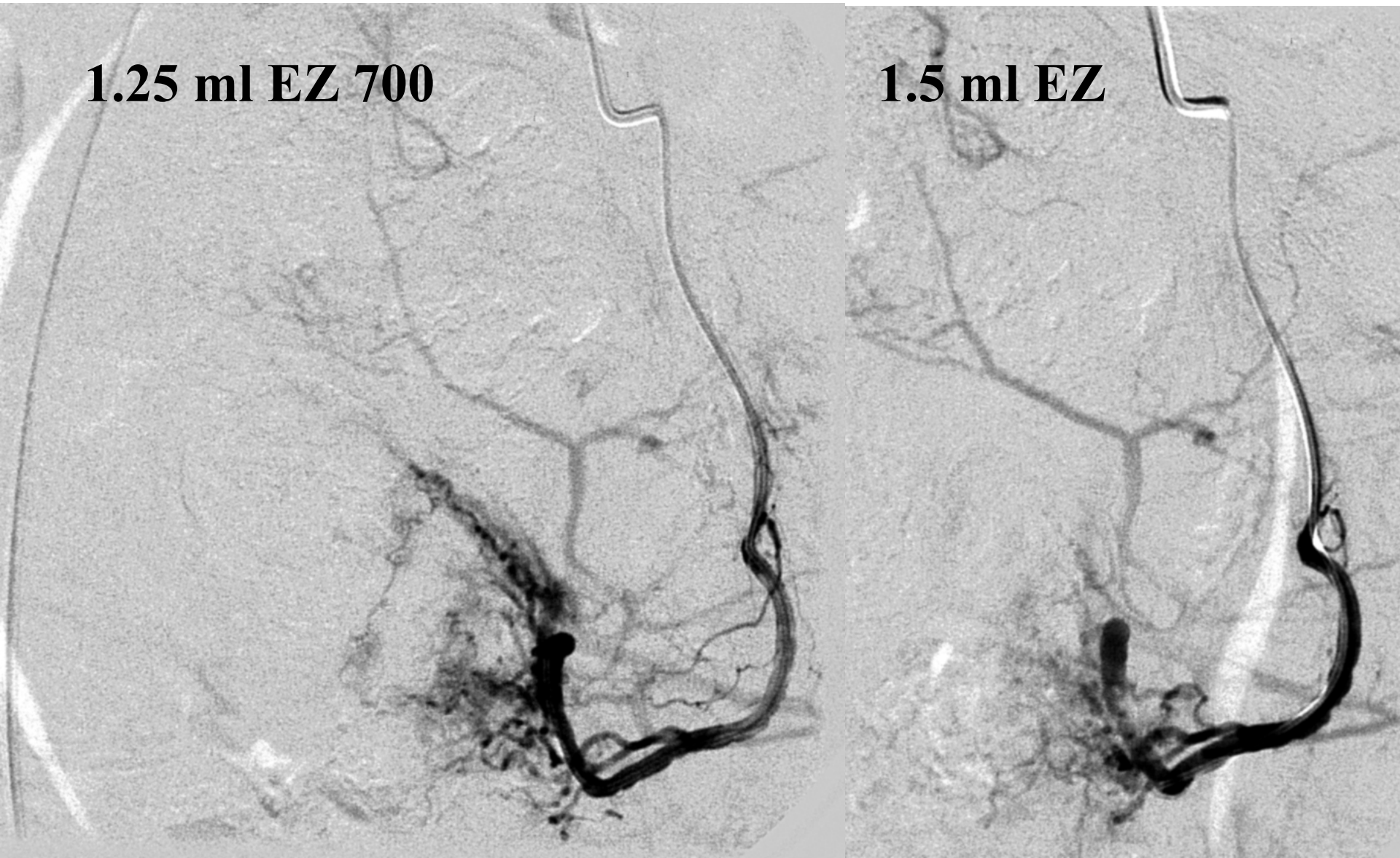

Sondierung rechte A. uterina: RAO, 40°

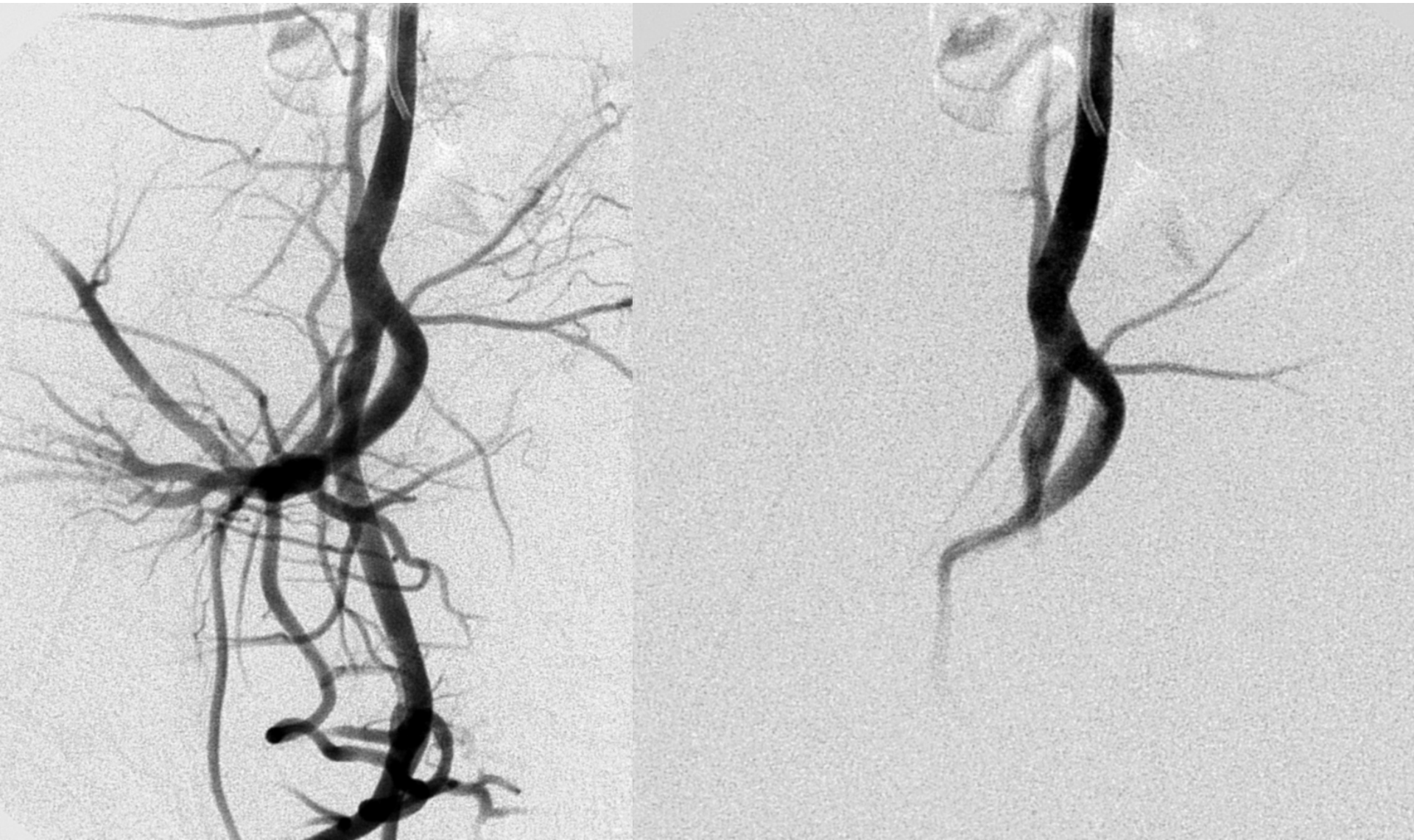

Sondierung rechte A. uterina: RAO, 10°

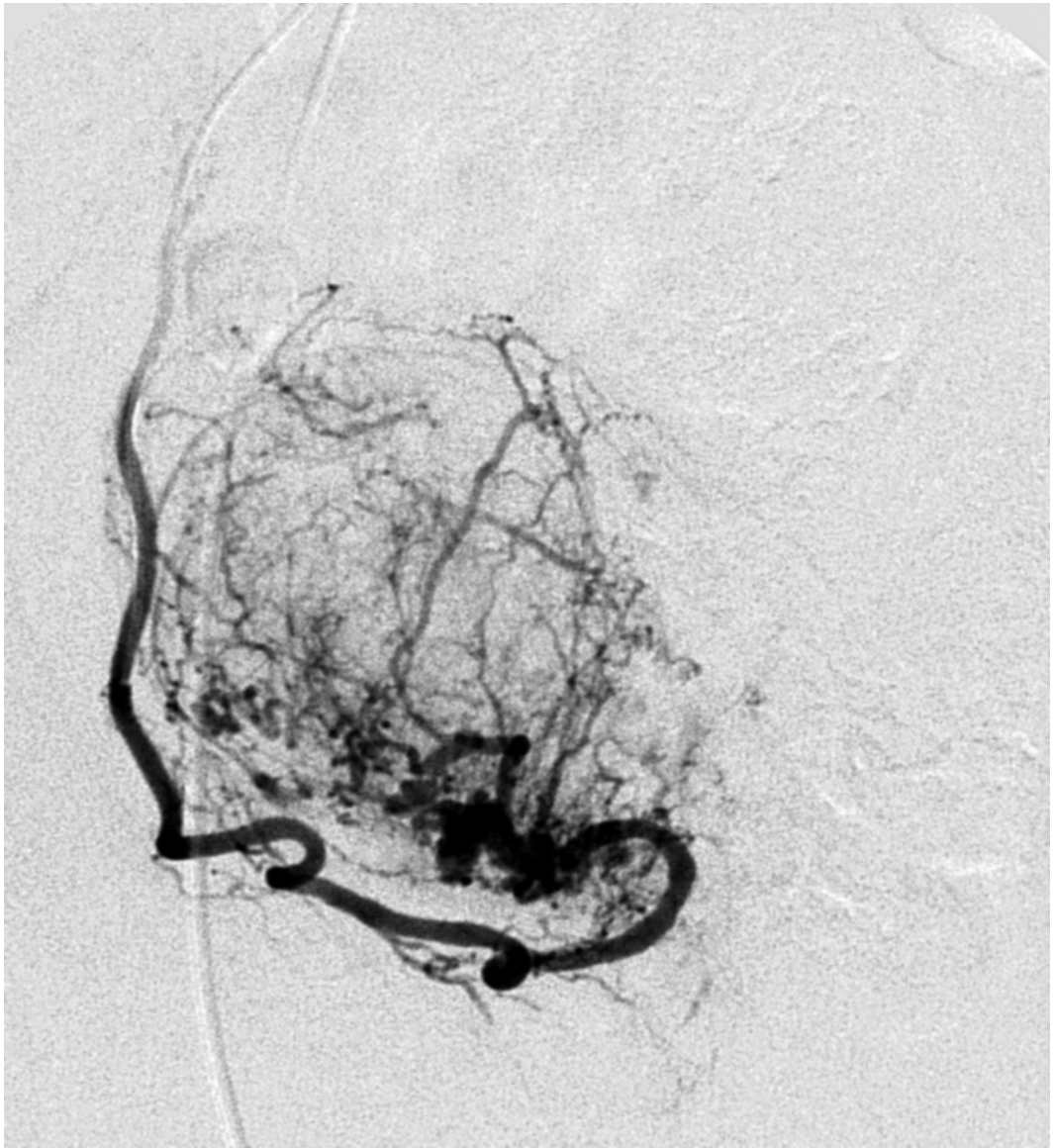

Embolisation:

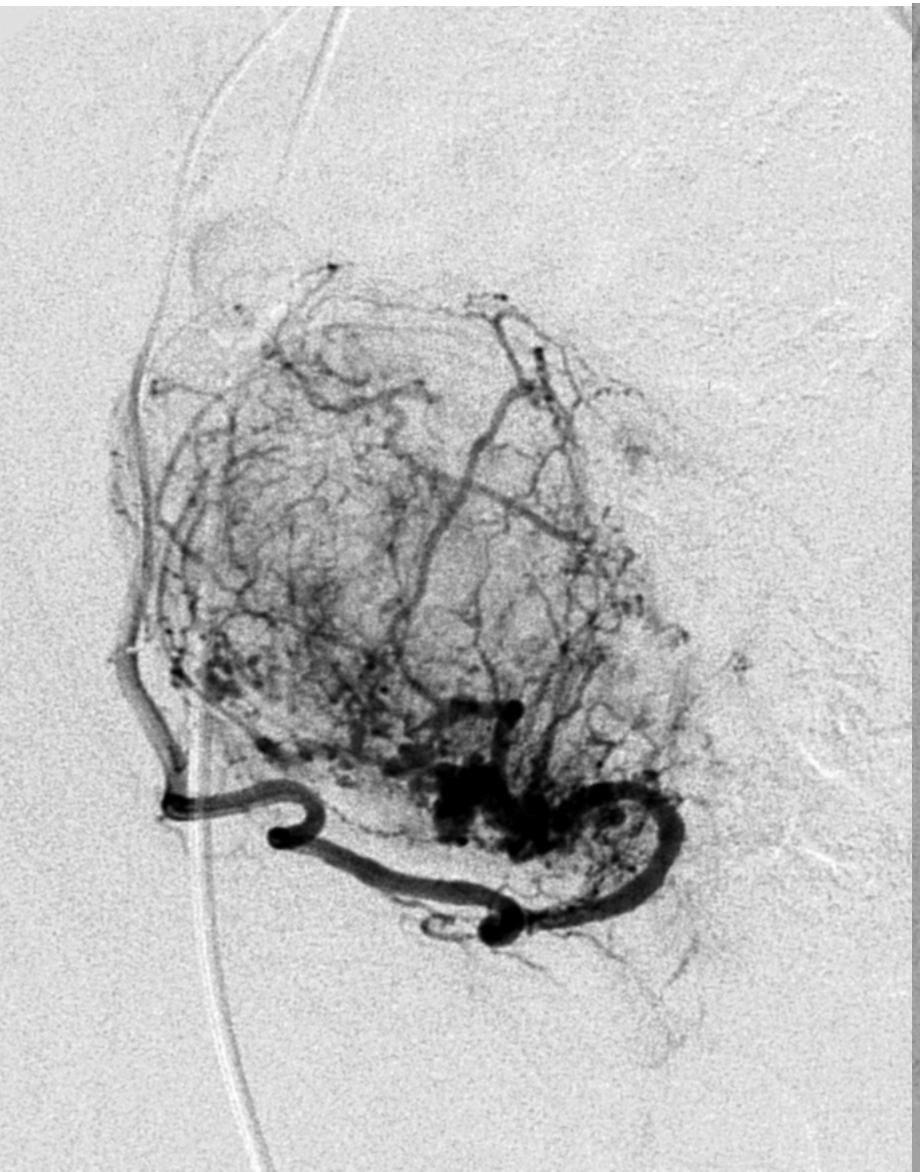

2. Fallbeispiel: linke A. uterina

40° RAO

40° LAO

2. Beispiel: Sondierung & Embolisation

2. Fall: Sondierung rechte A. uterina

40° LAO

40° RAO

2. Fall: Sondierung und Embolisation

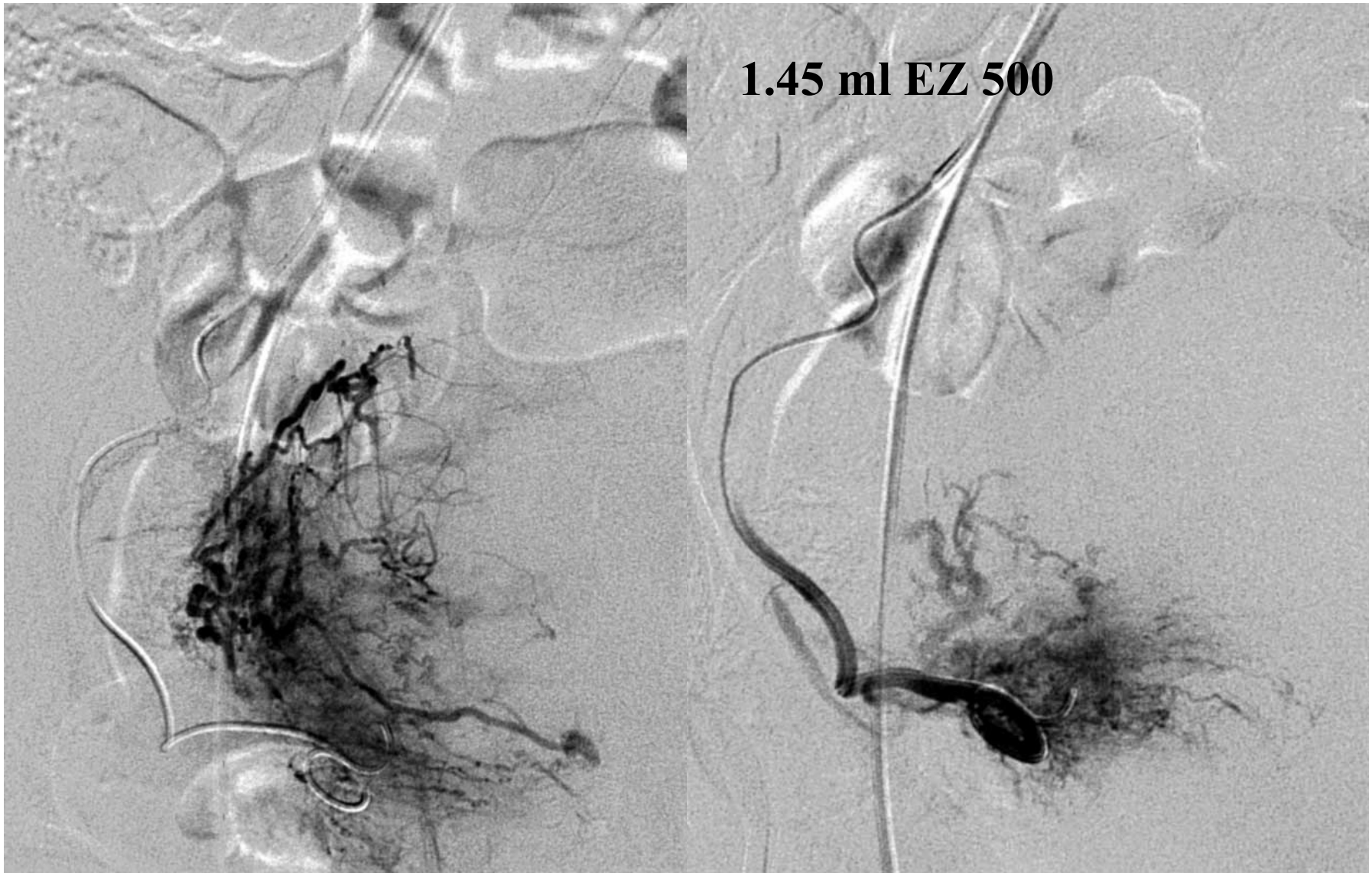

Spasmolytika und mehr ...

Intra-procedurale Gabe

- Spasmolytika (während / post-interventionell)
  - Buscopan 20 mg in 100 ml i.v.

- Antiemetika
  - Ondansetron (Zofran®, GlaxoSmithKline)
  - 4 mg in 100 ml i.v.

Schmerz-Management

Intra-proceduraler Schmerz

PCA: intravenös appliz., Patient-kontroll.Schmerzpumpe

- Piritramide (Dipidolor®) 300 mg/100ml
- 3mg (1ml) pro bolus
- Bolus jede 5 min, max. 6 Boli / Stunde
- Start vor der Embolisation der 2. Seite

Nebenwirkungen: Benommenheit, Obstipation, Übelkeit

Sphärische Embolisate: präzise Größe

Patientenvorbereitung: i.v. Zugang mit Beginn Tropfinfusi
Legen einer PCA (Standardtechnik für UAE)
➔Gewichts-adaptierte Einstellung (60, 70, 90 kg)
➔1. Bolus beginnt bereits 1 h präinterventionell

Analgesie während der Intervention in **suite:**
Konsequentes Anfordern von PCA-B
Novalgin 1 mg, 1 Amp. Buscopar

Analgesie auf der Statio
Fortführen der PCA / uslassversuch erst, wenn <25mg Morphin/24 hrs.
Begleitmedik
➔Novalg o g (bei Pat. mit normaler Nierenfunktion)
➔je 1 A s Kurzinfusion (bis 4 tgl.)
Entlassung erfolgter Oralisierung auf Tramal oder Valoron

Schmerzmedikation nach Entlassung

Schmerzproblem!

Sphärische Embolisate: präzise Größe

Eur Radiol
DOI 10.1007/s00330-009-1481-8

MAGNETIC RESONANCE

Anu Ruuskanen
Petri Sipola
Maritta Hippeläinen
Marion Wüstefeld
Hannu Manninen

Pain after uterine fibroid embolisation is associated with the severity of myometrial ischaemia on magnetic resonance imaging

Received: 23 January 2009
Revised: 6 May 2009
Accepted: 7 May 2009
© European Society of Radiology 2009

A. Ruuskanen (✉) · P. Sipola · H. Manninen
Department of Clinical Radiology, Kuopio University Hospital, P.O. Box 1777, FI-70211 Kuopio, Finland
e-mail: anu.ruuskanen@kuh.fi
Tel.: +358-447-174360
Fax: +358-17-174122

P. Sipola · H. Manninen
Institute of Medicine, Clinical Radiology, Kuopio University, P.O. Box 1627, FI-70211 Kuopio, Finland

M. Hippeläinen
Department of Obstetrics and Gynaecology, Kuopio University Hospital, P.O. Box 1777, FI-70211 Kuopio, Finland

M. Wüstefeld
Department of Anesthesiology and Intensive Care, Kuopio University Hospital, P.O. Box 1777, FI-70211 Kuopio, Finland

Abstract The purpose of the study was to evaluate uterine ischaemia after uterine artery embolisation (UAE) using magnetic resonance imaging and the role of myometrial and fibroid ischaemia in the pathogenesis of post-procedural pain. T1-weighted gradient echo imaging before and after contrast agent was performed on 62 women before and 24 h after UAE. We assessed the severity (mild, moderate, severe) of myometrial ischaemia, and the percentage and volume of ischaemic tissue in myometrium and fibroids. The Verbal Rating Scale was used to assess in-hospital post-procedural pain (1–3 mild, 4–6 moderate, 7–10 severe). Mean maximal pain was 7.7. Myometrial ischaemia was mild, moderate and severe in 29, 23 and 10 patients, respectively. Moderate or severe myometrial ischaemia ($p=0.041$), the percentage ($p=0.037$) and volume ($p=0.012$) of ischaemic tissue in the myometrium, and a large volume of embolic material ($p=0.038$) correlated with severe pain. In summary, pain following UAE is common and partly explained by myometrial ischaemia.

Keywords Uterine artery embolisation · Uterine fibroid · Magnetic resonance imaging · Myometrial ischaemia · Post-procedural pain

Sphärische Embolisate: präzise Größe

Upsizing der Embozene-Partikel:

➔die ersten beiden Vials bereits 700 µm

➔dann Wechsel auf 900 µm Größe

➔max. 5 vials pro Seite

Sphärische Embolisate: präzise Größe

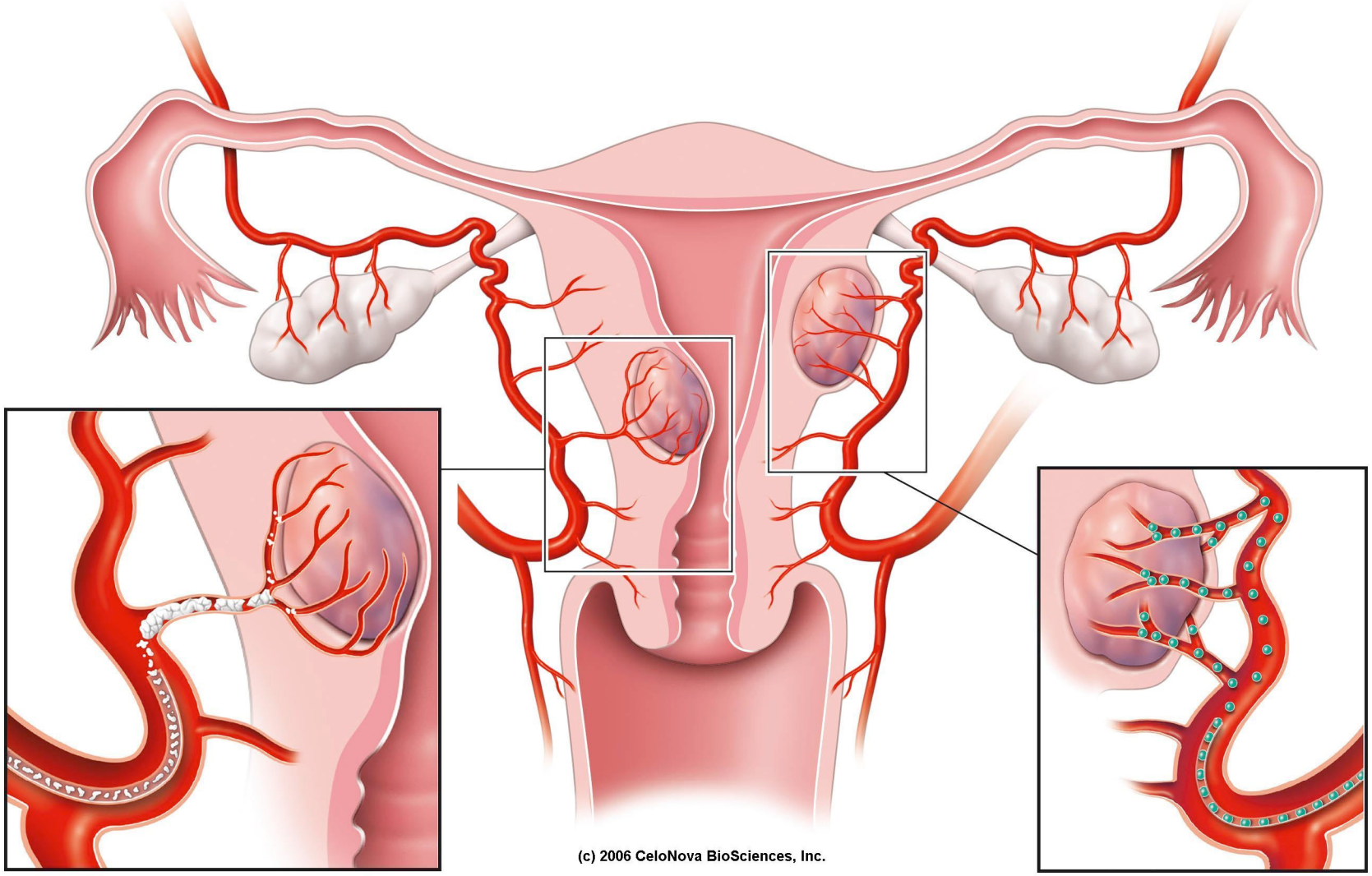

Sphärische Embolisate: präzise Größe

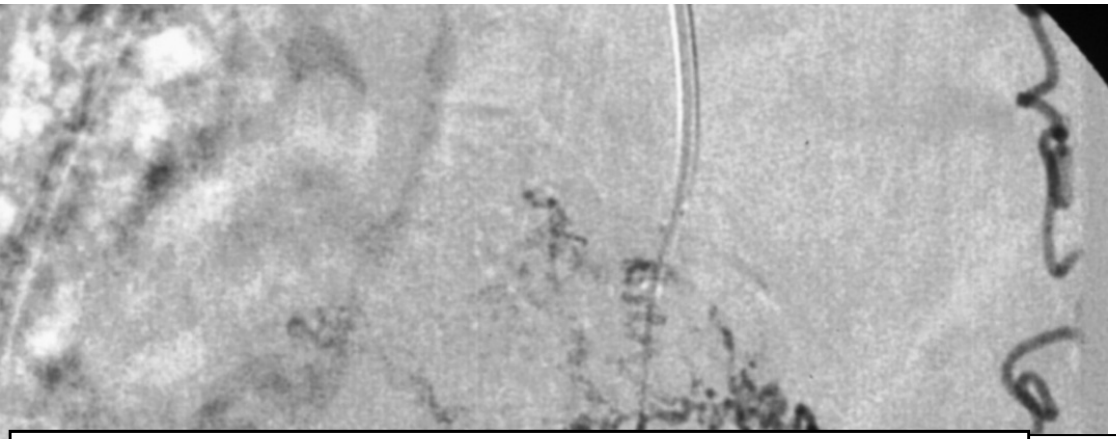

Wann die A. Ovarica erstmals sichtbar:

- von Beginn an?
- bei Zwischenkontrolle?

➔Was tun?

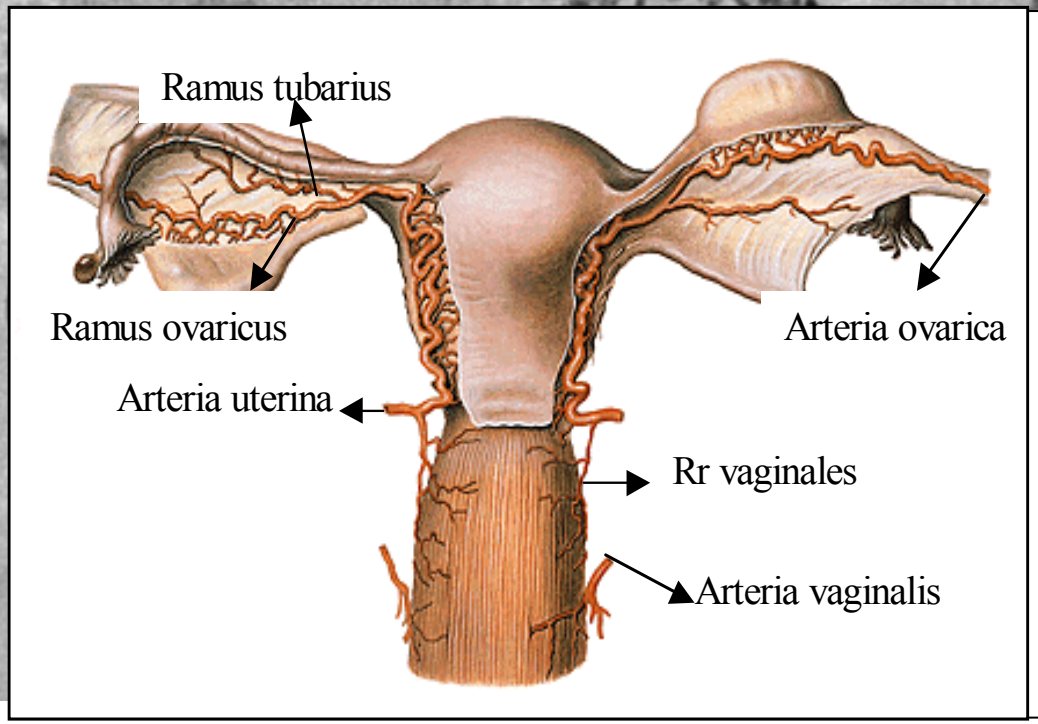

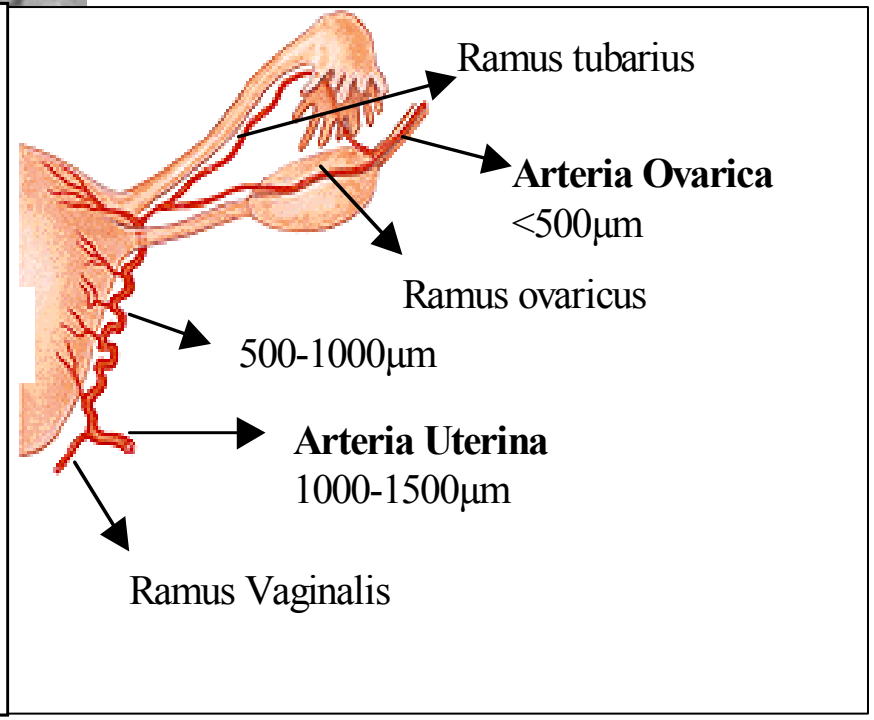

Sphärische Embolisate: präzise Größe

Sphärische Embolisate: präzise Größe

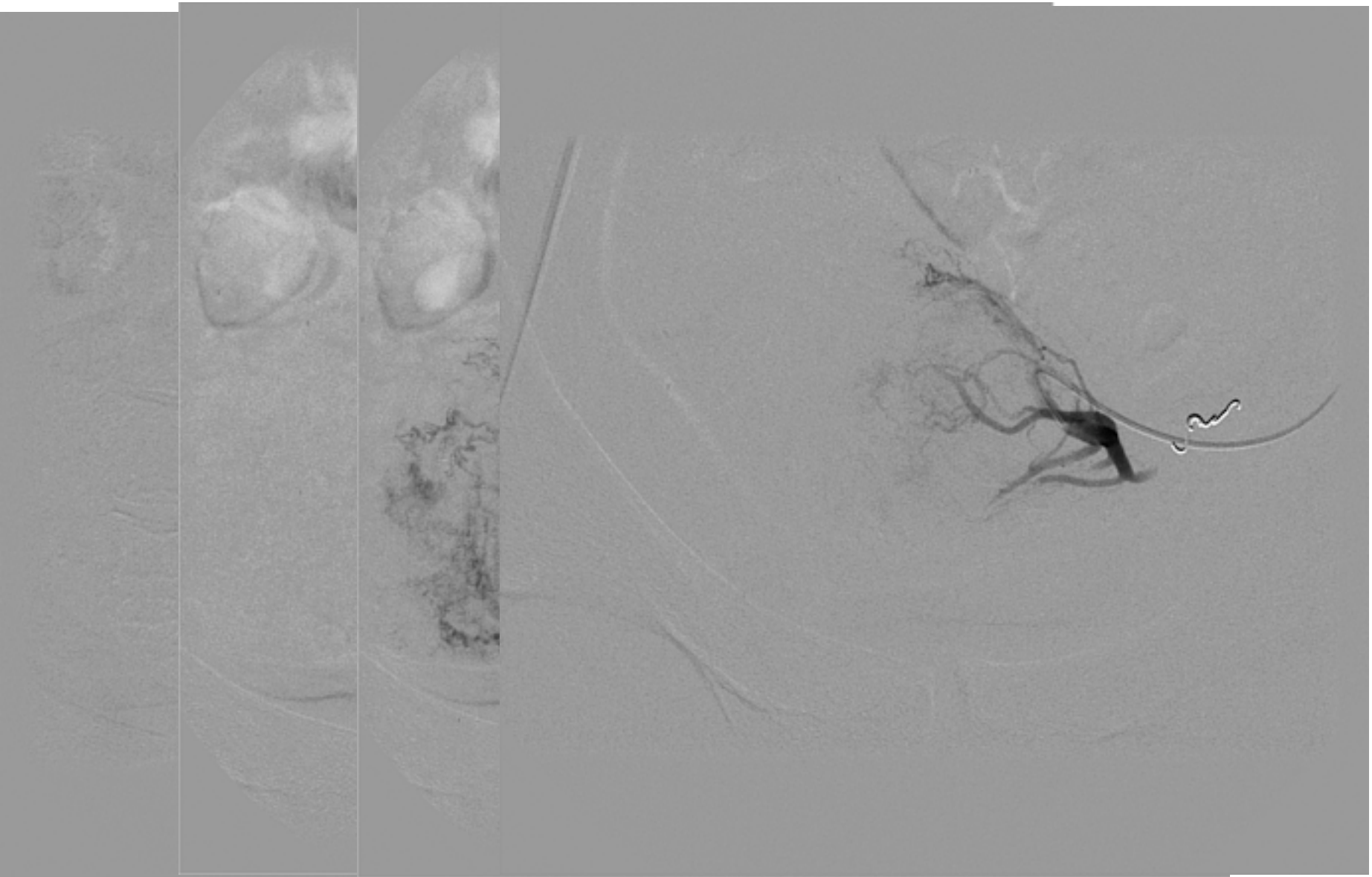

Technischer Erfolg

- Technisches Versagen 0-5%
  (frühe Arbeiten 2-8%)
- Anatomische Variationen
- Vasospasmus
- Unerfahrener Kollege
  (13 Min. Durchleuchtungszeit)

OBSTETRICS & GYNECOLOGY

ORIGINAL RESEARCH

Complications After Uterine Artery Embolization for Leiomyomas

James B. Spies, MD, Amy Spector, Antoinette R. Roth, MD, Chandra M. Baker, Lauren Mauro, and Kerry Murphy-Skrynarz, RN

OBJECTIVE: To determine the frequency and severity of complications that occur as a result of uterine artery embolization for leiomyomas.

METHODS: As part of an ongoing study of outcome after uterine embolization, prospective data regarding complications that occurred in 400 consecutive patients were gathered. Each patient had a minimum of a 3-month interval from the procedure at the time of analysis. Each complication was categorized and graded as to severity and outcome using the complication classification developed by the Society of Cardiovascular and Interventional Radiology (SCVIR) and a modified set of The American College of

reported as a result of embolization (Lanocita R, Patelli G, DiTolla G, Preafico C. A fatal complication of percutaneous transcatheter embolization for treatment of uterine fibroids [abstract]. Presented at the Society of Minimally Invasive Therapy/Center of Minimally Invasive Therapy 11th Annual Scientific Meeting; September 17, 1999; Boston, Massachusetts).[5] What is not yet clear is the incidence of the complications because few published series are of sufficient size to determine their true frequency.

As a part of our evaluation of this therapy, we have

RESULTS: There were no deaths and no major permanent injuries. One patient required hysterectomy as a result of a complication, and one patient had an undiagnosed leiomyosarcoma. There were ten in-hospital complications and an additional 27 complications within the first 30 days, with 34 patients experiencing a periprocedural complication for a rate of 8.5% (95% CI 6.0%, 11.7%). There were five serious complications (SCVIR class D), comprising 1.25% (95% CI 0.3%, 2.5%) of the study group. Using ACOG definitions for perioperative complications, the overall morbidity was 5% (95% CI 3.1%, 7.7%).

CONCLUSION: The short-term complication rate was low in women undergoing uterine embolization. (Obstet Gynecol 2002;100:873–80. © 2002 by The American College of Obstetricians and Gynecologists.)

SCVIR code	Description	*n*	Level of care (*n*)	Interventions (*n*)
C	*Required therapy minor hospitalization (<48 h)*			
	Recurrent or prolonged pain	4	1-d rehospitalization (4)	Intravenous narcotics (4)
	Leiomyoma passage	6	1-d rehospitalization (4) Office visit (2)	Hysteroscopy (2) Transfusion (2)
	Endometritis	2	1-d and 2-d rehospitalization (2)	Antibiotics (2) Dilation and curettage (2)
D	*Major therapy, unplanned increased level of care, prolonged hospitalization (>48 h)*			
	Pulmonary embolus	1	4-d rehospitalization	Anticoagulation
	Leiomyoma passage with endometritis	1	5-d rehospitalization	Antibiotics, hysteroscopy
	Leiomyoma passage with endometritis	1	5-d rehospitalization	Intravenous antibiotics
	Leiomyoma passage with hemorrhage	1	10-d rehospitalization	Transfusion, dilation and curettage, hysterectomy
	Arterial thrombosis	1	2-d intensive care	Thrombolytic therapy
E	*Permanent adverse sequelae*	0	NA	
F	*Death*	0	NA	

SCVIR = Society of Cardiovascular and Interventional Radiology; NA = not applicable.

Spies JB Obsterics & Gynecology 2002

SCVIR class	Description	No. of patients
A	No therapy, no consequences	1
B	Nominal therapy, observation, no consequences	27
C	Required therapy, minor hospitalization (<48 h)	12
D	Major therapy, unplanned increase in level of care, prolonged hospitalization (≥48 h)	5
E	Permanent adverse sequelae	0
F	Death	0
Total	Patients with complications*	42
Periprocedural	Patients with complications within 30 d of procedure	34

SCVIR = Society of Cardiovascular and Interventional Radiology.

Anzahl	Typ	Definition
Minorkomplikationen		
5	A	geringes punktionsassoziiertes Hämatom, Leistenschmerzen nach der Punktion, leichtes bis mäßiges Erbrechen, passagere Hypotonie
7	B	starkes punktionsassoziiertes Hämatom (schmerzhaft oder Hb-wirksam), starkes Erbrechen, sekundärer Myomabgang mit heftiger Blutung und ambulantem Arztbesuch (Zeitpunkt irrelevant), kurzzeitiges und passageres Fieber über 38 °C ohne weitere klinische Konsequenz
Majorkomplikationen		
1	C	operative Versorgung eines Leistenhämatoms, persistierendes Fieber über 38 °C, sekundärer Myomabgang mit heftiger Blutung und stationärer Aufnahme ohne weitere Konsequenz (Zeitpunkt irrelevant), neu aufgetretenes Fieber über 38 °C mit Neuansetzen von Antibiotika und kurzer stationärer Beobachtung
2	D	neu aufgetretenes Fieber über 38 °C und längere stationäre Beobachtung, ggf. Hysterektomie oder anderweitige septische Myomentfernung, sekundärer Myomabgang mit heftiger Blutung und stationärer Aufnahme und Hysteroskopie ohne oder mit Therapie, persistierende oder neuaufgetretene permanente Hb-wirksame Vaginalblutung mit Therapienotwendigkeit, ggf. Hysterektomie, passagere Amenorrhö
0	E	permanente Amenorrhö (bei Patientinnen mit regelrechtem Zyklus), nichtletale Lungenembolie
0	F	Tod

Eigene Ergebnisse:

Punktionsassoz. Hämatom=3

Starkes punktionsassoz. Hämatom=1

Myomabgang=8

Schweres Postembol. Syndrom=20

Myomabgang mit stat.Aufnahme=2

Hysterektomie=1

Chronische Schmierblutungen=2

Passagere Amenorrhea=2

Dauerhafte Amenorrhea=1

Komplikationen

Literatur:

- Mortalität der Intervention <0.1%
- Amenorrhoe 1-5%

(abweichende Ergebnisse für ältere Patientinnen)

- Myomabgang 1-2%

(3/4 submukösen Myomen zwischen 6 Wochen und 6 Monate)

- Infektion des embol. Myoms 1-2%
- Hysterektomie 3,5-5%
- Chronische Schmierblutungen ~5%

Klinische 3-Jahres-Ergebnisse nach Uterusmyom-embolisation

Clinical 3-Year Follow-Up of Uterine Fibroid Embolization

Autoren B. A. Radeleff[1], S. Satzl[1], M. Eiers[1], K. Fechtner[1], A. Hakim[1], S. Rimbach[2], G. W. Kauffmann[1], G. M. Richter[1]

Institute
[1] Abt. Radiodiagnostik, Universitätsklinikum Heidelberg
[2] Frauenklinik, Klinikum Konstanz

Tab. 5 Veränderung der klinischen Beschwerden nach Embolisation

Symptome	vor Emb.	p-Wert[1]	n. 1 Jahr	p-Wert[1]	n. 2 Jahren	p-Wert[1]	n. 3 Jahren
Hypermenorrhö[2]	4,4 ± 0,7	p = 0,0001	2,1 ± 0,5	p = 0,0042	1,7 ± 0,5	p = 0,0001	1,3 ± 0,6
Dysmenorrhö[3]	3,1 ± 1,5	p = 0,0001	1,1 ± 0,3	p = 0,0436	1,2 ± 0,2	p = 0,1484	1,2 ± 0,4
Dysurie[4]	3,1 ± 1,5	p = 0,0069	1,1 ± 0,3	p = 0,0028	1,1 ± 0,2	p = 0,9050	1,2 ± 0,4
Overall Health Status[5]	54,7 ± 20,1	p = 0,0001	90,5 ± 15,4	p = 0,2275	91,8 ± 5,6	p = 0,8578	91,3 ± 5,6
Therapiezufriedenheit[6]	n. a.	n. a.	2,9 ± 0,2	p = 0,0008	2,6 ± 0,3	p = 0,0396	2,7 ± 0,5

[1] Die p-Werte wurden mittels des Wilcoxon-Vorzeichen-Rang-Tests ermittelt. Aufgezeigt werden die p-Werte für statistische Unterschiede zwischen den Verlaufskontrollen präinterventionell und nach einem Jahr postinterventionell, zwischen einem und zwei Jahren postinterventionell und zwischen zwei und drei Jahren postinterventionell.
[2] 1 = normale Monatsblutung bis 5 = extreme Monatsblutung
[3] 1 = keine Menstruations-assoziierte Schmerzen bis 5 = extreme Schmerzen
[4] 1 = keine Myom-assoziierten Dysurie bis 5 = extreme Dysurie
[5] Wertebereich zwischen 1 – 100, mit 100 als Maximalwert für Wohlbefinden
[6] – 3 („extrem unzufrieden“) bis + 3 („extrem zufrieden“)

Fortschr Röntgenstr 2007; 179: 593-600
DOI: 10.1055/s-2007-963043

OBSTETRICS & GYNECOLOGY

Long-Term Outcome of Uterine Artery Embolization of Leiomyomata

James B. Spies, MD, Jill Bruno, DO, Ferenc Czeyda-Pommersheim, MD, Shantel T. Magee, MD, Susan A. Ascher, MD, and Reena C. Jha MD

OBJECTIVE: To determine the long-term outcome from uterine artery embolization for leiomyomata.

METHODS: In a prospective study, 200 consecutive patients treated with uterine embolization were each followed for 5 years. Outcome, including symptom status compared with baseline, reinterventions, menstrual status, and satisfaction were recorded. Summary statistics were used to report baseline characteristics and outcome at each interval. Predictors of subsequent interventions, failure, and satisfaction with treatment were analyzed using logistic regression and Cox proportional hazards models. Failure was defined as subsequent hysterectomy, definitive myomectomy, repeat embolization, or failure of symptom improvement at the patient's final follow-up interval.

RESULTS: Of the 200 patients initially treated, 5-year follow-up was completed in 182 (91%), with 18 patients missing. At 5 years after treatment, 73% had continued symptom control, whereas 36 (20%) had failed or recurred.

CONCLUSION: Uterine embolization provides durable symptom relief for most patients, with a 25% chance of failure of symptom control or recurrence over the course of a 5-year follow-up.

(Obstet Gynecol 2005;106:933–9)

LEVEL OF EVIDENCE: II-3

Uterine artery embolization first was reported for the treatment for leiomyomata in 1995.[1] Since that time, there has been rapid growth in the use of this treatment, and there has been considerable research into its outcome. Although it has become recognized as an effective therapeutic alternative to hysterectomy and myomectomy,[2] there are remain-

RESULTS: Of the 200 patients initially treated, 5-year follow-up was completed in 182 (91%), with 18 patients missing. At 5 years after treatment, 73% had continued symptom control, whereas 36 (20%) had failed or recurred.

volumes greater than the median (RR 2.16, 95% CI 1.03–4.51, $P = .036$). After adjustment, patients in the first tertile of leiomyoma volume reduction (≤ 30.5%) were 3 times more likely to be dissatisfied with outcome compared with women in the third tertile (≥ 56.3% volume reduction) (RR 3.23; 95% CI 1 07–9.81, $P = .037$).

From the Department of Radiology, Georgetown University Hospital, Washington, DC.

Presented in part at the Society of Interventional Radiology 2005 Annual Meeting in New Orleans, Louisiana, March 31, 2005, and at Advances in Uterine Leiomyoma Research: 2nd NIH International Congress, February 25, 2005, Bethesda, Maryland.

Corresponding author: James B. Spies MD, Department of Radiology, CG 201, Georgetown University Hospital, 3800 Reservoir Road NW, Washington, DC 20007-2113; e-mail: spiesj@gunet.georgetown.edu.

© 2005 by The American College of Obstetricians and Gynecologists. Published by Lippincott Williams & Wilkins.

ISSN: 0029-7844/05

uterine embolization in 1997 and treated 200 consecutive patients, with outcome data collected prospectively. The initial results of this group of patients at 12 months after therapy have been reported previously.[7] In that report, 90% of patients had improved menstrual bleeding and 91% had improved pain and pressure (bulk symptoms) at 12 months. The follow-up interval in that initial report ranged from 12 minimum up to 21 months. During that interval, there was reintervention in 10.5% of patients. These patients have now completed 5 years follow-up, and their outcomes are presented here. The intent of this phase of the study is to estimate the durability of symptom control, the rate of reintervention, and the level of long-term patient satisfaction. In addition, we hoped to determine predictors of long-term satisfaction and, conversely, the predictors of failure.

OBSTETRICS & GYNECOLOGY

Long-Term Outcome of Uterine Artery Embolization of Leiomyomata

James B. Spies, MD, Jill Bruno, DO, Ferenc Czeyda-Pommersheim, MD, Shantel T. Magee, MD, Susan A. Ascher, MD, and Reena C. Jha MD

OBJECTIVE: To determine the long-term outcome from uterine artery embolization for leiomyomata.

METHODS: In a prospective study, 200 consecutive patients treated with uterine embolization were each followed for 5 years. Outcome, including symptom status compared with baseline, reinterventions, menstrual status, and satisfaction were recorded. Summary statistics were used to report baseline characteristics and outcome at each interval. Predictors of subsequent interventions, failure, and satisfaction with treatment were analyzed using logistic regression and Cox proportional hazards models. Failure was defined as subsequent hysterectomy, definitive myomectomy, repeat embolization, or failure of symptom improvement at the patient's final follow-up interval.

RESULTS: Of the 200 patients initially treated, 5-year follow-up was completed in 182 (91%), with 18 patients missing. At 5 years after treatment, 73% had continued symptom control, whereas 36 (20%) had failed or recurred. There had been 25 hysterectomies (13.7%), 8 myomectomies (4.4%), and 3 repeat embolizations (1.6%). Long-term failure was more likely in those not improved at 1 year (relative risk [RR] 5.73; 95% confidence interval [CI] 2.32–14.12, $P < .001$) and in those with baseline leiomyoma volumes greater than the median (RR 2.18; 95% CI 1.05–4.51, $P = .036$). After adjustment, patients in the first tertile of leiomyoma volume reduction (≤ 30.5%) were 3 times more likely to be dissatisfied with outcome compared with women in the third tertile (≥ 56.3% volume reduction) (RR 3.23; 95% CI 1 07–9.81, $P = .037$).

CONCLUSION: Uterine embolization provides durable symptom relief for most patients, with a 25% chance of failure of symptom control or recurrence over the course of a 5-year follow-up.

(Obstet Gynecol 2005;106:933–9)

LEVEL OF EVIDENCE: II-3

Uterine artery embolization first was reported for the treatment for leiomyomata in 1995.[1] Since that time, there has been rapid growth in the use of this treatment, and there has been considerable research into its outcome. Although it has become recognized as an effective therapeutic alternative to hysterectomy and myomectomy,[2] there are remaining questions regarding its long-term outcome. Most published studies have reported outcomes in the first 12 months,[3–5] but as of yet there are few long-term studies. The longest follow-up in a published study in the English literature to date was 3 years in a retrospective comparison of myomectomy and embolization by Broder et al.[6]

We began a study assessing the outcome from uterine embolization in 1997 and treated 200 consecutive patients, with outcome data collected prospectively. The initial results of this group of patients at 12 months after therapy have been reported previously.[7] In that report, 90% of patients had improved menstrual bleeding and 91% had improved pain and

Symptomfreiheit (abhängig vom Myomtyp): 78-94%
•Besserung Schmerzen/abdom. Druckgefühl: 79-96%
•Patienten profitierten von der UAE: 79-85%

© 2005 by The American College of Obstetricians and Gynecologists. Published by Lippincott Williams & Wilkins.
ISSN: 0029-7844/05

hoped to determine predictors of long-term satisfaction and, conversely, the predictors of failure.

Klinischer Mißerfolg

- Ausbleiben eines klinischen Benefits nach einer beidseitigen UAE

- berichtet in ca. 10-20%
  - inkomplette Embolisation
  - Sehr große Myome (>11 cm)
  - Begleitende oder alleinige Adenomyosis
  - Nichterkannte/nichtbehandelte Kollateralen

MRT: Devaskularisation

Heidelberger UAE-Ergebnisse

Devaskularisation der Myome* im MRT nach 10 Tagen

Devaskularisation in %	N=60	
87,5-100%	40	**93,3%**
75-87,49%	16	
62,5%-74,9%	1	**6,7%**
50-62,49%	3	
37,5-49,9%	0	
25-37,49%	0	**0%**
12,5-24,9%	0	
0-12,49%	0	

* des dominanten Myoms

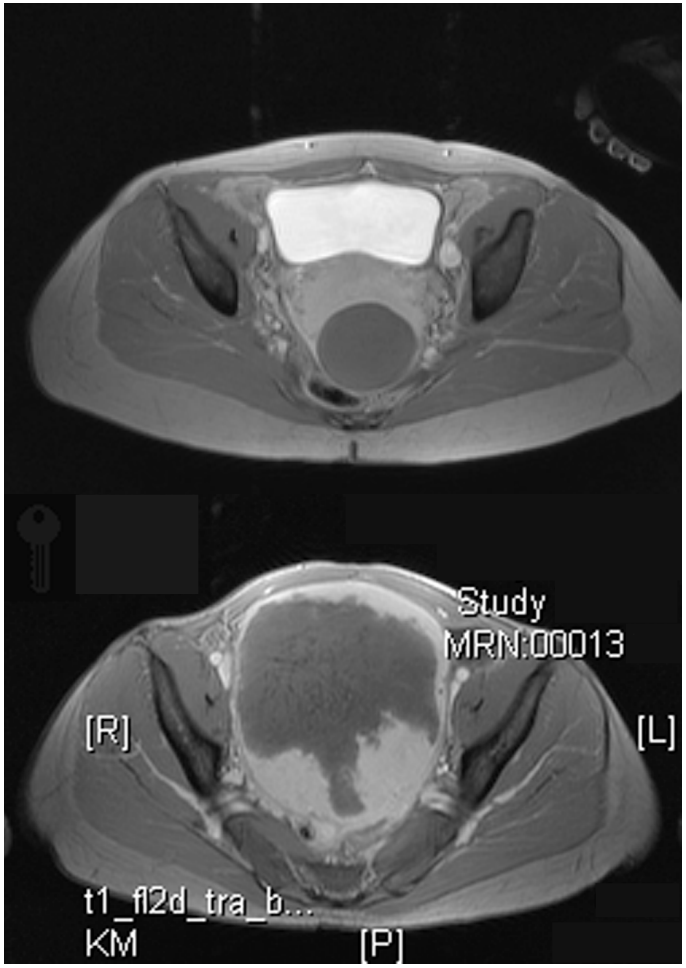

MRT: Devaskularisation

Heidelberg UAE-Ergebnisse

Inkomplette Devaskularisation der Myome* im MRT nach 10 Tagen

Devaskularisation in %	N=60	
62,5%-74,9%	1	**6,7%**
50-62,49%	3	

* des dominanten Myoms aller embolisierten Patientinnen

Keine Konsequenzen

Re-Embolisation

lehnte Re-Embolisation ab

Re-Embolisation

Revaskularisation ist ein Problem!!

Patient A. F. 40 Jahre

- **Hypermenorrhoe**
- **Dyspareunie**

Aber Management ist möglich!!

Pat. 1. vor Emb.

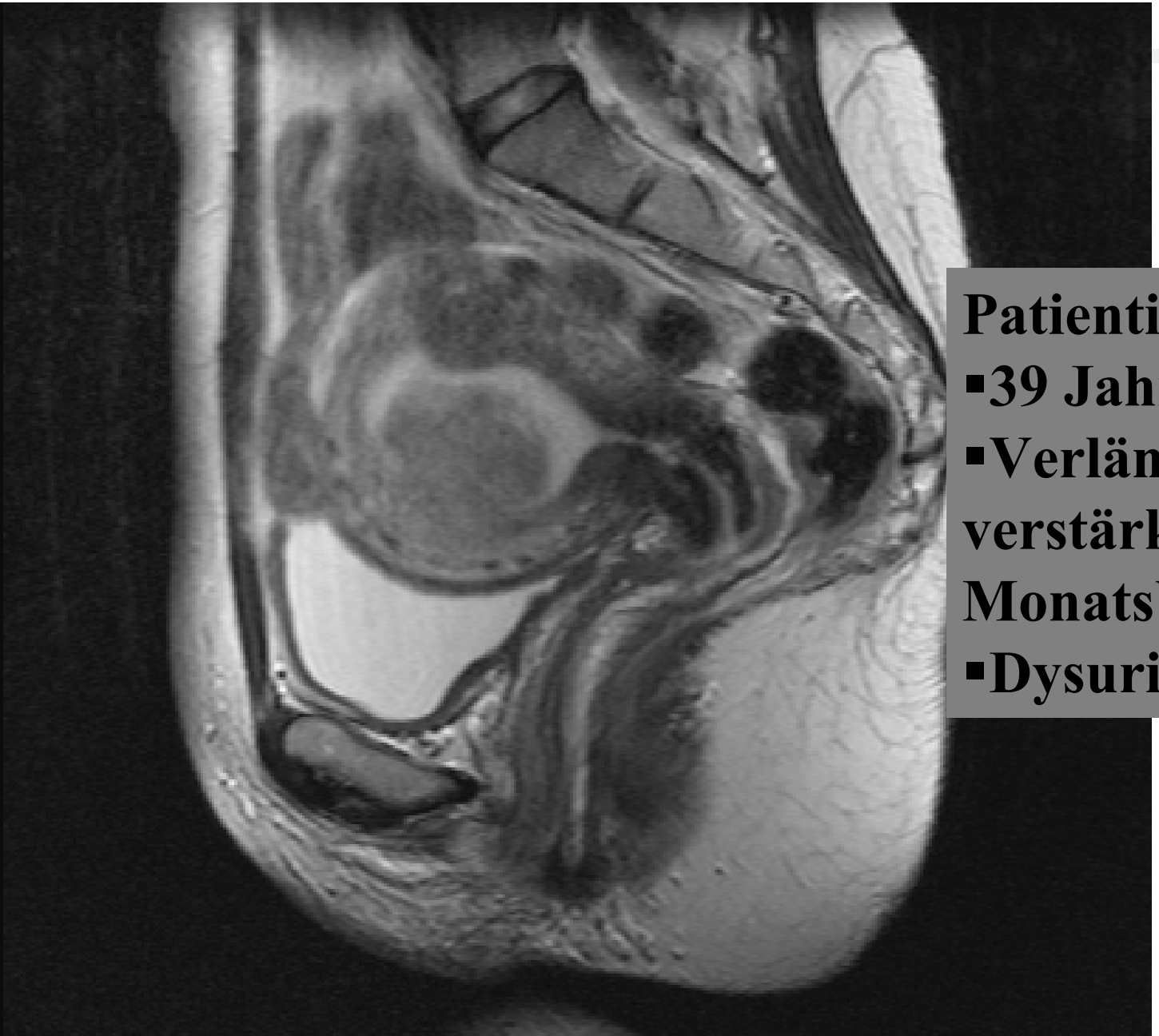

Patientin Fr. J. L.

- **39 Jahre**
- **Verlängerte und verstärkte Monatsblutung**
- **Dysurie**

10 Tage nach Embolisation

nach 12 Monaten nach UAE

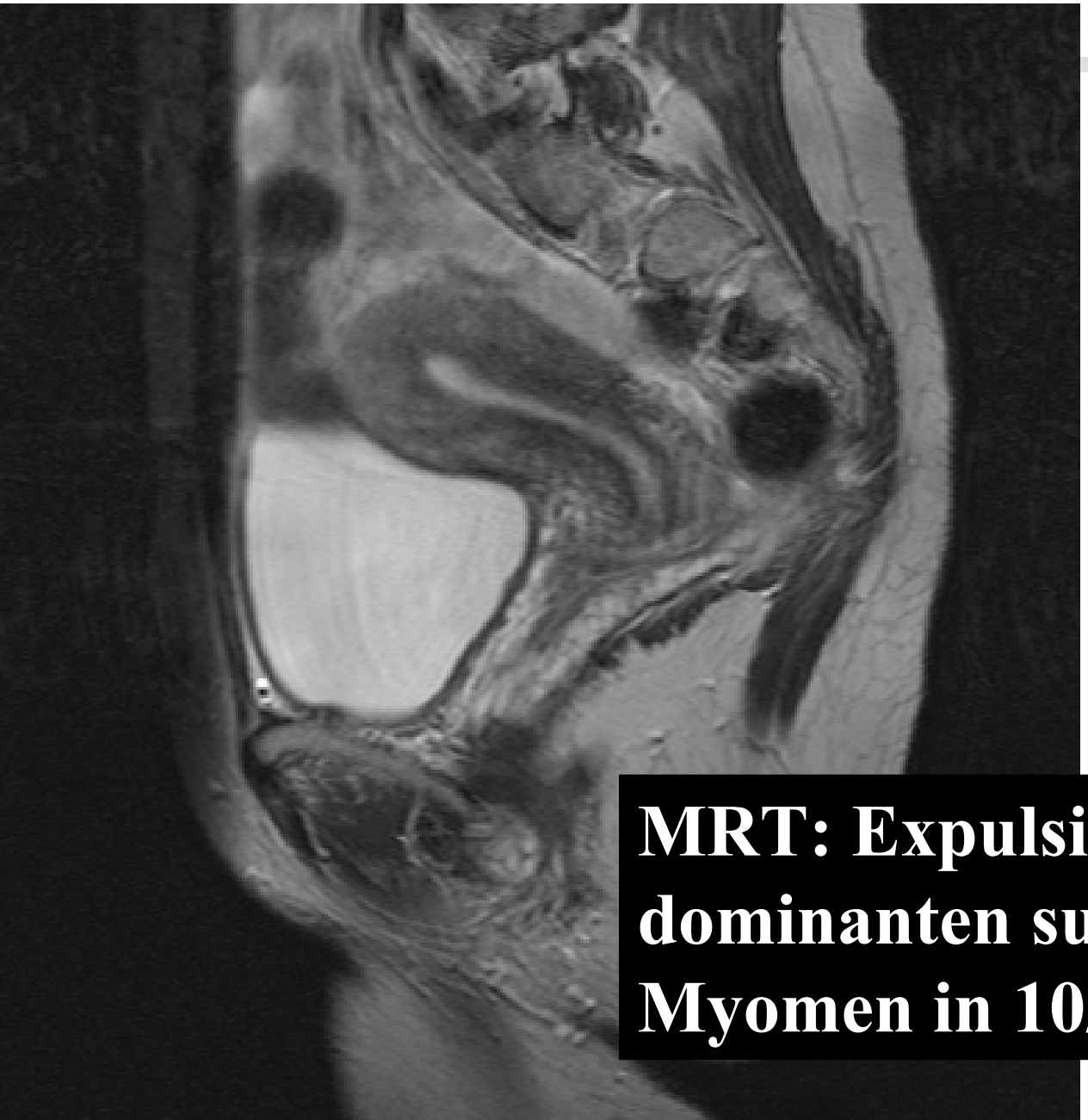

MRT: Expulsion von dominanten submukösen Myomen in 10/21 Patientinnen

Patient 2. vor Embolisation

Pat. L.K. 50 Jahre alt

- **Hypermennorhoe**
- **Anämie**
- **Dysurie**
- **Dyspareunie**

Pat. 2. 10 Tage nach Embolisation

Pat. 2. vor UAE / nach 12 Monaten

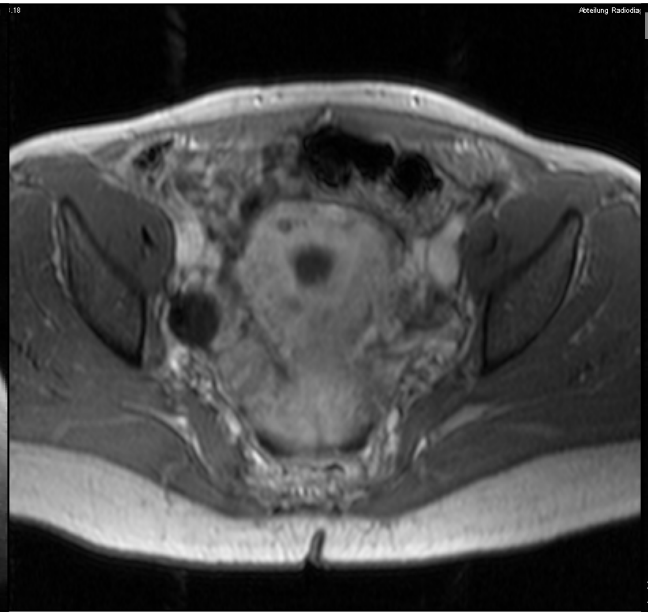

MRT: Volumen Reduktion

- **Schrumpfen des Myoms kurz nach der Embolisation beginnend**
- **Schrumpfungs-Peak zwischen 3-6 Monaten**
- **Schrumpfung bis nach 12 Monate nach der Embolisation[1,2]**
- **Submuköse Myome schrumpfen signifikant[3] stärker als intramurale[3]**
- **Häufigere Expulsion von submukösen Myomen als von intramuralen**

- **Keine direkte Korrelation zwischen der Volumenreduktion und einer Symptombesserung**

1. Kröncke TJ, Hamm B. Radiologe 2003; 43:624-633.
2. Pelage JP, Guaou NG, Jha RC, Ascher SM, Spies JB. Radiology 2004; 230:803-809
3. Spies JB, Roth AR, Jha RC, et al. Radiology 2002; 222:45-52.

Zusammenfassung

Erfolgsfaktoren

Patientenauswahl (Myomtyp, max. Durchmesser)
Embolisations Technik (Mikrokatheter)
Embozene Partikel (700/900 / Adenomyosis: 500)

Risiken

Partikelgröße (OV-Anastomose)
Endpunkt (Revaskularisation)

Komplikationen

Angiographie-assoziiert
OV-Anastomose